

This is an Open Access article licensed under the terms of the Creative Commons Attribution-NonCommercial-NoDerivs 3.0 License (www.karger.com/OA-license), applicable to the online version of the article only. Distribution for non-commercial purposes only.

Neuroblastoma in a 55-Year-Old Patient: A Case Report

Cornelia Then^a Kathleen Ebelt^a Alexandra Langer^a
Doris Mayr^b Ralf Schmidmaier^a Fuat Oduncu^a

^aDepartment of Hematology/Oncology, Medizinische Klinik Innenstadt, University Hospital Munich, and ^bInstitute of Pathology, Ludwigs-Maximilians-University Munich, Munich, Germany

Key Words

Neuroblastoma · Chemotherapy · Multiple myeloma · Response to treatment

Abstract

Background: Neuroblastomas account for 97% of all neuroblastic tumors and for approximately 15% of all pediatric cancer fatalities. However, in adults neuroblastoma is a very rare finding.

Case Report: Here, we present the case of a 55-year-old patient who was diagnosed with neuroblastoma stage IV one year after the false diagnosis of a non-secretory multiple myeloma.

Results: The patient received six cycles of a chemotherapy protocol with cisplatin, etoposide and vindesine alternating with vincristine, dacarbazine, ifosfamide and doxorubicin, but the response to treatment was insufficient (stable disease).

Conclusion: The standard chemotherapy protocols used for children are not sufficient for adult patients. Different treatment approaches are needed to improve the prognosis of adult patients with neuroblastoma.

Introduction

Neuroblastic tumors derive from neuroectodermal cells of the peripheral neural crest that are destined for the adrenal medulla and sympathetic nervous system. After birth, the extramedullary para-aortic paraganglia gradually atrophy and normally disappear by the age of two to three years. The malignant transformation of residual microscopic neuroblastic nodules may result from a failure of these cells to respond adequately to the normal signals that stimulate differentiation or apoptosis.

Neuroblastoma is almost exclusively a disease of children. Approximately 40% are diagnosed before one year of age; the average age at diagnosis is about 17 months. Only 2% of cases are found in patients over the age of 10 years [1]. The diagnosis of neuroblastoma in adults has been reported in several case reports [2–4]. Notably, most of

the described patients were young adults with a median age below 35 years at diagnosis. Here, we report the case of a 55-year-old patient diagnosed with neuroblastoma stage IV.

Case Report

A 55-year-old man was diagnosed with a poorly differentiated non-secretory multiple myeloma in January 2009 by biopsy from a mediastinal tumor in a peripheral hospital. CT scan showed osteolytic lesions in the thoracic vertebral bodies 6–10. Apart from hypertension, there was no further recorded medical history. In January and March 2009, the patient received radiation therapy of the thoracic vertebral bodies 6–10 with a total of 60 gray. In March 2010, chemotherapy with bortezomib and dexamethasone was initiated because of advancing osteolytic lesions. In April 2010, the patient was referred to our hospital with an increasing pain in the pelvis and the os sacrum.

Physical examination revealed a palpable solid supraclavicular tumor of 2 × 3 cm in size. In the laboratory tests, a hemoglobin level of 9.5 g/dl, a platelet count of $11 \times 10^9/l$ and a white blood cell count of 3.3×10^9 cells/l with 75% polymorphonuclear leukocytes and 15% lymphocytes were observed. The LDH (540 U/l; normal < 250 U/l), the CRP (4.7 mg/dl; normal < 0.5 mg/dl) and the serum neuron-specific enolase (335 ng/ml; normal < 16.3 ng/ml) were elevated. The excretion of dopamine (1,197 µg/24 h; normal < 500 mg/24 h), metanephrine (1.39 mg/24 h; normal < 1.2 mg/24 h), mandelic acid (44.8 mg/24 h; normal < 6.8 mg/24 h) and homovanillic acid (75.8 mg/24 h; normal < 8 mg/24 h) was increased, whereas the excretion of adrenaline was normal.

Immunophenotyping of the peripheral blood showed an inverse CD4/CD8 T cell ratio, but no plasma cells or leukemic lymphoma cells. The bone marrow biopsy displayed dysplastic erythroid and megakaryocytic changes with no sign of the previously diagnosed multiple myeloma. However, blast cells were found in the bone marrow smear (fig. 1a). Immunohistological examination revealed a blastic neoplasm with profound marrow infiltration, fibrosis and displacement of the hematopoiesis, strongly expressing the neuronal markers neuron-specific enolase (fig. 1b), chromogranin and CD56, thus suggesting the diagnosis of a neuroblastoma. The plasma cell marker VS38c was positive; however, CD138 was negative. Fluorescence in situ hybridization revealed a hyperploid karyotype. NMYC amplification and 1p-deletion were not detectable. Histological examination of the surgically removed tumorous supraclavicular lymph node showed a stroma-poor neuroblastoma with low differentiation and a low mitosis-karyorrhexis index, grade 2, according to the Hughes classification.

The subsequent staging examinations (PET-CT scan of the cranium, neck, chest and abdomen; fig. 2a; MRT scan of the cranium and the thoracic and lumbar spine; metaiodobenzylguanidine (MIBG) scintigraphy; fig. 2b) revealed a stage IV disease with disseminated manifestations (meningeal, supraclavicular, paravertebral and osseous tumors as well as a diffuse bone marrow infiltration).

Treatment with cisplatin, etoposide and vindesine alternating with vincristine, dacarbazine, ifosfamide and doxorubicin analogous to the German NB-2004-HR study, which is designed for the treatment of children (Neuroblastoma Study Centre, Pediatric Clinic, University of Cologne, Cologne, Germany), was initiated after completion of the staging examinations. Chemotherapy was started with 75% of the intended dose and was escalated to 100% since the patient tolerated the treatment very well. The response to treatment, however, was insufficient. After six cycles of chemotherapy, the neuron-specific enolase decreased to 45.8 ng/ml, but there was less change in the excretion of dopamine (896 µg/24 h), mandelic acid (14.6 mg/24 h) and homovanillic acid (33.9 mg/24 h). The tumorous lesions were unchanged, as determined by PET-CT and the bone marrow biopsy displayed persistent neuroblastoma infiltration. The treatment will be continued including high-dose chemotherapy followed by autologous peripheral blood stem cell transplantation and MIBG-radionuclide therapy.

Discussion

The diagnosis of a neuroblastic tumor in an adult patient is so rare that both clinicians and pathologists tend to exclude neuroblastoma from differential diagnosis when the patient is an adult. The patient described here had osseous lesions in addition to the

mediastinal tumor and the bone marrow infiltration. This was probably – together with the positive plasma cell marker VS38c – the reason for the initial false diagnosis of a non-secretory multiple myeloma.

The 55-year-old patient showed a poor response to chemotherapy treatment. This is in line with previously reported adult or adolescent patients with neuroblastoma, for whom the ultimate outcome is generally poor, regardless of the initial disease stage [5, 6]. The prognosis of neuroblastoma strongly depends on the age at diagnosis, with significantly better survival rates for younger children [1]. Thus, the treatment of neuroblastoma not only depends on the disease stage, but also on the patient's age. Localized tumors in children can mostly be cured by surgery only, or sometimes may even be self-limiting. However, disseminated tumors in older children require an aggressive multimodality approach including surgical resection, radiation therapy and high-dose chemotherapy with hematopoietic stem cell rescue. Yet, if treated with the standard protocols used for children, even the survival rate for adolescents is low [5]. More aggressive or innovative therapeutic approaches are needed for older patients. Ablative chemotherapy followed by autologous stem cell transplantation leads to prolonged survival in advanced stage diseases [7]. Tandem transplants show some promise with progression-free survival rates of over 50% at up to seven years [8]. However, for children older than 18 months with disseminated disease, the survival rates remain low at approximately 30%. Therefore, new tumor-specific strategies are under investigation. Immunotherapy with antibodies targeted at GD2 (a disialoganglioside on the surface of neuroblastoma) produced promising preliminary results [9], and may also be labeled with ^{131}I [10]. The radioisotope iodine-131-MIBG in conjunction with hematopoietic stem cell transplantation is effective in the treatment of advanced stage disease [11, 12]. Novel approaches in the pursuit for MYC-targeting therapies are currently under observation for tumors with NMYC amplification, which is one of the clearest indicators of aggressive and chemotherapy-refractory disease [13]. Knockdown of XAB2, a part of the co-receptor complex that inhibits differentiation induction by retinoic acid, enhances the differentiating effect of all-trans retinoic acid on resistant neuroblastoma cells [14]. Successful allogeneic stem cell transplantation has been reported in a 7-year-old boy with stage IV neuroblastoma [15].

However, in addition to survival prolongation, the life quality of the patient is an important factor. Due to the rareness of neuroblastomas in adults, the data about their prognosis is scarce, but the described cases were mostly diagnosed in advanced stage disease and had an unfavorable outcome. The older the patient is at diagnosis, the longer and the more indolent the disease course appears to be [5, 6]. As long as remission is not an accessible intent, a satisfactory aim may also be disease stabilization, avoiding more serious therapeutic side effects. The patient described here had a long disease course with few symptoms and retained a good life quality beside the disseminated malignant disease for now more than 20 months after the first diagnosis. To properly evaluate the efficacy and toxicity of new or more aggressive therapeutic strategies for adolescent and adult patients with neuroblastoma, a central collection of the data is necessary.

Disclosure Statement

The authors have no conflict of interest or competing interests.

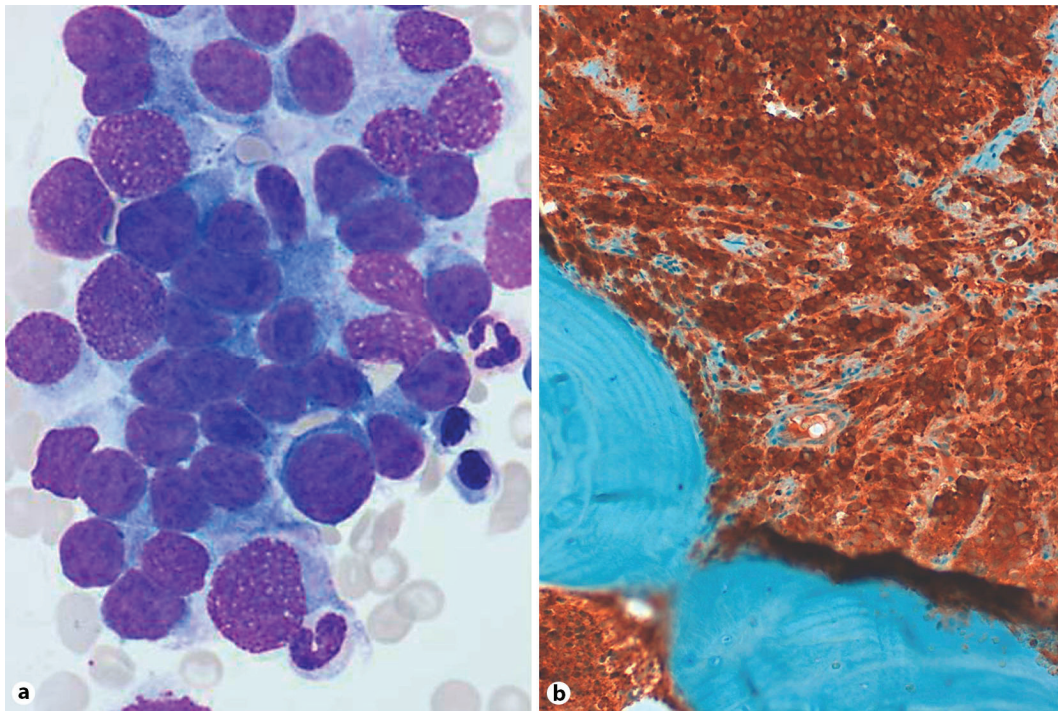


Fig. 1. **a** Bone marrow smear displaying blast cells. **b** Histological examination of the bone marrow biopsy revealing a profound marrow infiltration with displacement of the hematopoiesis (neuron-specific enolase staining).

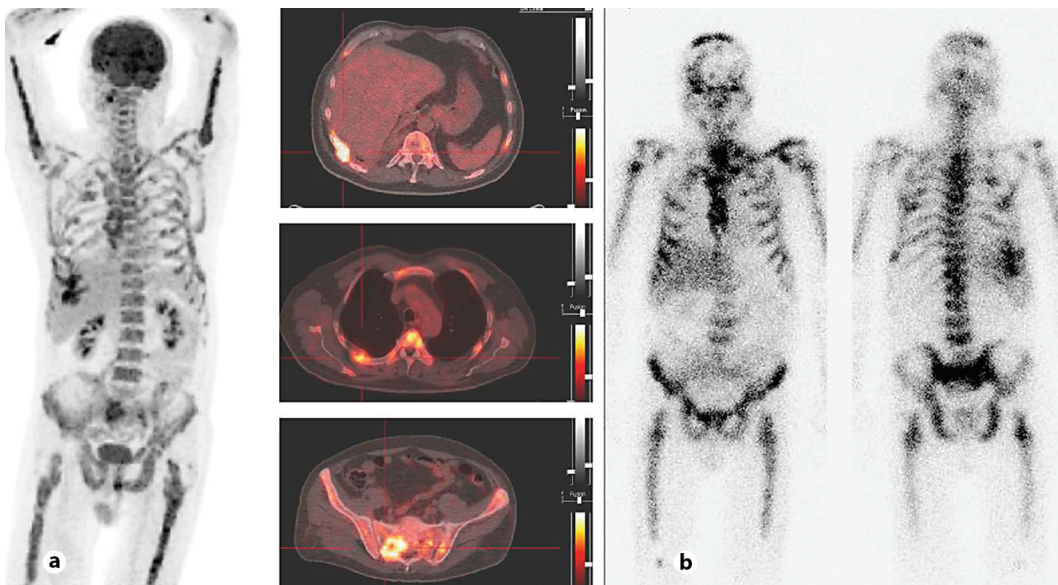


Fig. 2. **a** Diffuse pathological glucose uptake in the bone marrow of the hollow bones and the vertebral bodies in the PET and PET-CT scan. **b** Diffuse iodine-131-MIBG uptake in the bone marrow, including the calvarium, as determined by MIBG scintigraphy.

References

- 1 London WB, Boni L, Simon T, Berthold F, Twist C, Schmidt ML, Castleberry RP, Matthay KK, Cohn SL, De Bernardi B: The role of age in neuroblastoma risk stratification: the German, Italian, and children's oncology group perspectives. *Cancer Lett* 2005;228:257–266.
- 2 Zerrweck-López C, Quijano-Orvañanos F, Montañez-Ramírez H, Murillo-Zolezzi A, Toledo-Valdovinos S, Padilla-Longoria R: Neuroblastoma in the adult. Case report. *Cir Cir* 2009;77:397–401.
- 3 Urios JI, Garceran LR, Rosell TV: Neuroblastoma in an adult causing spinal cord compression: report of a case and review of the literature. *Paraplegia* 1989;27:394–401.
- 4 Allan SG, Cornbleet MA, Carmichael J, Arnott SJ, Smyth JF: Adult neuroblastoma. Report of three cases and review of the literature. *Cancer* 1986;57:2419–2421.
- 5 Conte M, De Bernardi B, Milanaccio C, Michelazzi A, Rizzo A, Montobbio G, Parodi S, Haupt R: Malignant neuroblastic tumors in adolescents. *Cancer Lett* 2005;228:271–274.
- 6 Franks LM, Bollen A, Seeger RC, Stram DO, Matthay KK: Neuroblastoma in adults and adolescents: an indolent course with poor survival. *Cancer* 1997;79:2028–2035.
- 7 Moon SB, Park KW, Jung SE, Youn WJ: Neuroblastoma: treatment outcome after incomplete resection of primary tumors. *Pediatr Surg Int* 2009;25:789–793.
- 8 George RE, Li S, Medeiros-Nancarrow C, Neuberger D, Marcus K, Shamberger RC, Pulsipher M, Grupp SA, Diller L: High-risk neuroblastoma treated with tandem autologous peripheral-blood stem cell-supported transplantation: long-term survival update. *J Clin Oncol* 2006;24:2891–2896.
- 9 Cheung NK, Sowers R, Vickers AJ, Cheung IY, Kushner BH, Gorlick R: FCGR2A polymorphism is correlated with clinical outcome after immunotherapy of neuroblastoma with anti-GD2 antibody and granulocyte macrophage colony-stimulating factor. *J Clin Oncol* 2006;24:2885–2890.
- 10 Dauer LT, St Germain J, Williamson MJ, Zanzonico P, Modak S, Cheung NK, Divgi C: Whole-body clearance kinetics and external dosimetry of 131I-3F8 monoclonal antibody for radioimmunotherapy of neuroblastoma. *Health Phys* 2007;92:33–39.
- 11 Lessig MK: The role of 131I-MIBG in high-risk neuroblastoma treatment. *J Pediatr Oncol Nurs* 2009;26:208–216.
- 12 George RE, Diller L, Bernstein ML: Pharmacotherapy of neuroblastoma. *Expert Opin Pharmacother* 2010.
- 13 Gustafson WC, Weiss WA: Myc proteins as therapeutic targets. *Oncogene* 2010;29:1249–1259.
- 14 Ohnuma-Ishikawa K, Morio T, Yamada T, Sugawara Y, Ono M, Nagasawa M, Yasuda A, Morimoto C, Ohnuma K, Dang NH, Hosoi H, Verdin E, Mizutani S: Knockdown of XAB2 enhances all-trans retinoic acid-induced cellular differentiation in all-trans retinoic acid-sensitive and -resistant cancer cells. *Cancer Res* 2007;67:1019–1029.
- 15 Lu QY, Wang Z, Li P, Niu XQ, Zhang P, Zhao JN: Treatment of stage IV neuroblastoma with allogeneic hematopoietic stem cell transplantation in children. *Zhongguo Dang Dai Er Ke Za Zhi* 2008;10:464–466.