

Transjugular Intrahepatic Portosystemic Shunt

Andreas Ochs

Department of Internal Medicine, Evangelisches Diakonie Krankenhaus, Teaching Hospital of the Medical Faculty, University of Freiburg, Freiburg, Germany

Key Words

Portal hypertension · Variceal bleeding · Ascites · Hepatorenal syndrome · TIPS · Budd-Chiari syndrome · Hepatic hydrothorax · Endoscopic band ligation · Cirrhosis · Hepatic encephalopathy

Abstract

The transjugular intrahepatic portosystemic shunt (TIPS) is an interventional treatment resulting in decompression of the portal system by creation of a side-to-side portosystemic anastomosis. Since its introduction 16 years ago, more than 1,000 publications have appeared demonstrating broad acceptance and increasing clinical use. This review summarizes our present knowledge about technical aspects and complications, follow-up of patients and indications. A technical success rate near 100% and a low occurrence of complications clearly depend on the skills of the operator. The follow-up of the TIPS patient has to assess shunt patency, liver function, hepatic encephalopathy and the possible development of hepatocellular carcinoma. Shunt patency can best be monitored by duplex sonography and can avoid routine radiological revision. Short-term patency may be improved by anticoagulation, while such a treatment does not influence long-term patency. Stent grafts covered with expanded polytetrafluoroethylene show promising long-term patency comparable with that of surgical shunts. With respect to the indications of TIPS, much is known about treatment of variceal bleeding and refrac-

tory ascites. The thirteen randomized studies that are available to date show that survival is comparable in patients receiving TIPS or endoscopic treatment for acute or recurrent variceal bleeding. Another group comprises patients with refractory ascites and related complications, such as hepatorenal syndrome and hepatic hydrothorax. It has been demonstrated that TIPS improves these complications. Five randomized studies comparing TIPS with paracentesis and one study comparing TIPS with the peritoneo-venous shunt showed good response of ascites but controversial results on survival. In addition, TIPS has been successfully applied to patients with Budd-Chiari syndrome, portal vein thrombosis, before liver transplantation, and for the treatment of ectopic variceal bleeding.

Copyright © 2005 S. Karger AG, Basel

Introduction

Transjugular intrahepatic portosystemic shunts (TIPS) are used to create a low-resistance channel between the hepatic vein and the intrahepatic portion of the portal vein by deployment of an expandable metal stent. After animal experiments in the 70s and 80s, the first TIPS was inserted in a patient in Freiburg, Germany in 1988 [1–5]. Table 1 shows indications for which TIPS has been used in the last 16 years. This paper evaluates these indications. Other articles in this issue address the pathophysiology and treatment options for these conditions.

Table 1. Reported indications for TIPS

<i>Variceal bleeding</i>	
Acute variceal bleeding	
Prevention of rebleeding	
Treatment of ectopic varices	
Primary prophylaxis of variceal bleeding	
Portal hypertensive gastropathy	
<i>Ascites</i>	
Refractory ascites	
Hepatorenal syndrome types 1 and 2	
Hepatic hydrothorax	
Closure of umbilical hernia	
<i>Miscellaneous</i>	
Budd-Chiari syndrome	
Veno-occlusive disease	
Non-cavernomatous portal vein thrombosis	
Portal hypertension in malignancies	
Treatment of portal hypertension prior to gastrointestinal surgery	
Prior to orthotopic liver transplantation	

Technique and Procedural Complications

TIPS function like side-to-side portocaval shunts, but their placement does not require anesthesia and major surgery. After puncture of the (right) jugular vein, a catheter is placed into the right or middle hepatic vein. A needle is placed into the (right) portal branch of the portal vein under fluoroscopic and sonographic guidance. This is the most demanding step and in approximately 10% of cases a backward direction of puncture is needed. Table 2 shows acute and long-term complications and their treatment and prevention [6–9]. In experienced hands, the technical success rate approaches 100% and procedural mortality amounts to 1%. The creation of TIPS has considerable consequences on hepatic and systemic perfusion. Depending on the diameter of the shunt, portal vein flow is partially or completely diverted from the liver [10]. Hepatic perfusion depends on the arterial buffer reserve. This reserve is negatively correlated with the Child-Pugh score and may explain the high rate of mortality in advanced liver disease [11, 12]. Pre-TIPS

Table 2. Acute and chronic complications after implantation of a TIPS

Technical complications	Frequency %	Significance	Treatment/prevention
Procedural 30-day mortality	<1–6		experienced team
Pneumothorax	<1	significant	thorax drainage
Inadvertent arterial puncture with neck hematoma	<0–1	minor	compression (rarely ventilation)/sonographic guidance
Heart arrhythmias	<5?	usually none	guidewire removal
Hepatic capsule perforation	<?	potentially lethal	embolization of puncture tract/sonographic guidance
Bile duct or gallbladder puncture/fistula	<10	may cause shunt thrombosis/occlusion	covered stents, cholecystectomy
Portal vein wall injury	<1	thrombus formation	stenting of injured region
Extra-hepatic portal vein laceration	<1	lethal	covered stents/avoid central puncture site
Stent dislodgment	<1	minor	endovascular removal
Radiation injury	<?	minor	experienced team
Contrast dye: allergic reaction	<10–20	significant	i.v. corticosteroids, antihistaminics
Contrast dye: renal impairment	<10?	significant	CO ₂ angiography
Septic complications	<10?	significant	antibiotics/avoid TIPS in acute infection
Heart failure – infarction	<10	significant	medical treatment/pre-TIPS echocardiography, patient selection
Haemolysis	<10	minor	often self limited/covered stents?
Acute liver failure	<?	significant	OLT, artificial liver support/careful patient selection
Hepatic encephalopathy	–70%	significant	medical treatment, shunt reduction or occlusion, OLT/ small diameter shunts, careful patient selection, embolization of collaterals without shunt
Shunt occlusion or stenosis	–90%	significant	anticoagulation in case of thrombotic complications/ covered stents (stent grafts)

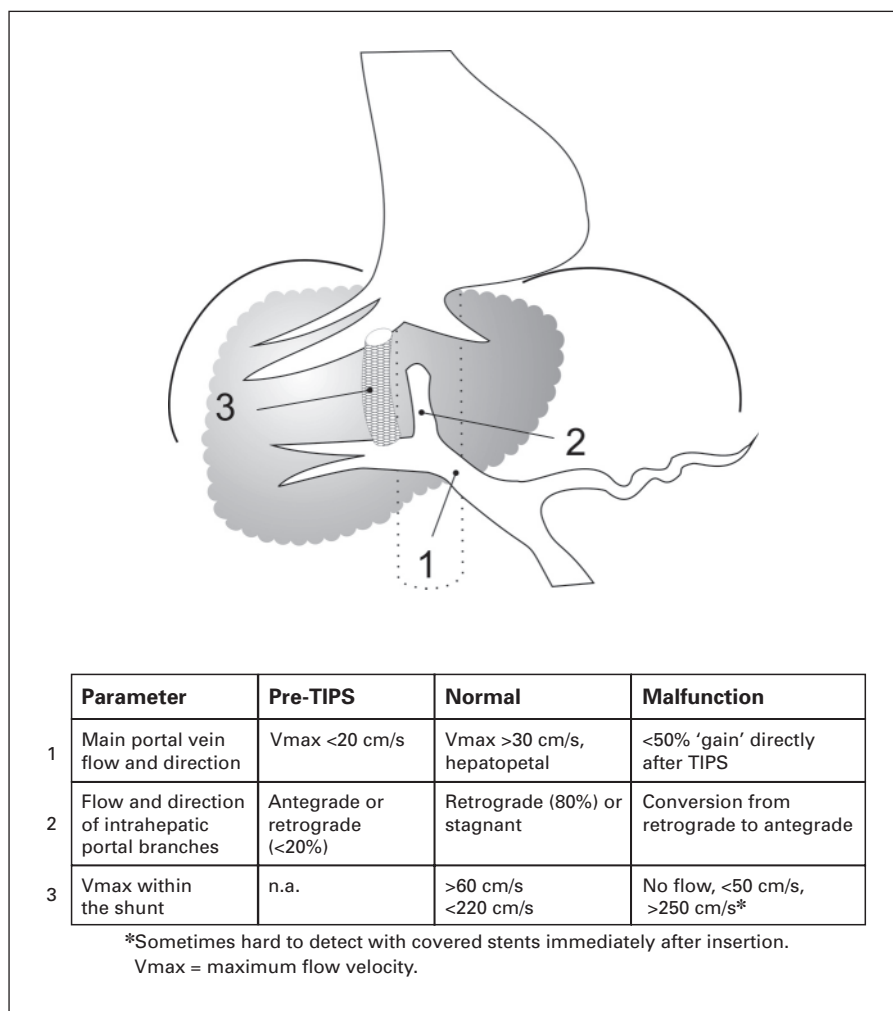


Fig. 1. Schematic representation of TIPS and important parameters in sonographic follow-up.

hepatic perfusion can be evaluated invasively [11] or with cine MRT imaging [13]. Systemic, cardiopulmonary and renal hemodynamics are also influenced by the TIPS procedure. Cardiac output, mean pulmonary arterial pressure and pulmonary capillary wedged pressure increase after opening of the shunt, while systemic vascular resistance decreases. These changes are temporary [14, 15]. With time, renal perfusion is enhanced, suggesting the existence of a hepatorenal reflex in humans [16, 17]. In patients with refractory ascites, TIPS reduces the activity of the renin-aldosterone-angiotensin system and restores sodium handling [18–20]. Hepatic encephalopathy (HE) is a major complication of all portocaval shunts and occurs in up to 70% of cases [6]. The incidence correlates with the shunt diameter and liver function. Other risk factors are older age, alcohol abuse, pre-TIPS HE and the requirement of mechanical ventilation [21, 22]. Proton

magnetic resonance spectroscopy can monitor changes in brain metabolism after TIPS [23]; a small diameter shunt has to be considered for patients with a high risk for HE. Debilitating HE may require shunt reduction, occlusion, or orthotopic liver transplantation (OLT) [24–28]. Similarly, hepatic function may deteriorate after TIPS. Several scoring systems exist to predict poor outcome after the procedure. Newer models include renal function, which proved to be an important determinant in patients with refractory ascites [29–33].

Shunt insufficiency or occlusion may occur at any time during follow-up, thus a suitable monitoring of shunt function is mandatory. Color-coded Doppler sonography can diagnose clinically relevant shunt malfunction, if several parameters are investigated (fig. 1) [34–39]. Shunt revision is performed on clinical needs, thus reappearance of varices or ascites. Early shunt occlusion is mainly

a result of thrombosis, which can be avoided by anticoagulation. Trapidil and ticlopidine with initial heparin reduced intimal proliferation [40]. Late shunt malfunction occurs in up to 80% of cases during follow-up. Recently, the use of expanded polytetrafluoroethylene (ePTFE)-covered stents resulted in a primary patency rate of 84% at 1 year by Kaplan-Meier analysis [41–45]. Broad application is currently hampered by high costs.

Bleeding of Collaterals

Variceal bleeding from esophageal, gastric or ectopic collaterals is a major cause of mortality in liver cirrhosis. Therapeutic options include medical [46–48] (vasoconstrictive/vasoactive drugs) and endoscopic (sclerotherapy/ligation) treatments [46, 49, 50]. TIPS has been used for ongoing variceal bleeding, for the prevention of rebleeding and for the treatment of gastric, fundal and ectopic varices. Medical and endoscopic treatments are covered extensively in this issue. Briefly, a recent meta-analysis evaluated 13 studies on patients with ongoing bleeding. Ligation appeared to be the most effective treatment; it was significantly more successful than vasoconstrictive treatment (vasopressin/terlipressin) or vasoactive treatment (somatostatin/octreotide) treatment, but was not statistically superior to sclerotherapy [51]. To prevent rebleeding, β -blockers with and without combination therapy have been used. Sclerotherapy and endoscopic band ligation reduce the risk of rebleeding but have no influence on survival [52–54].

Acute Variceal Bleeding

Several studies have addressed the role of TIPS as a rescue treatment after sclerotherapy failure [55–62]. TIPS stopped active bleeding in 90–100% of cases. Early rebleeding occurred in 16–30% of the patients and the early mortality amounted to 17–60%. Sepsis, requirement of mechanical ventilation after aspiration and renal failure are predictors of poor survival. Thus, patients in this group should not be accepted for salvage TIPS.

Prevention of Recurrent Bleeding

Uncontrolled studies [7, 63] and 13 randomized studies demonstrated that TIPS treatment reduces rebleeding from gastroesophageal varices. A recent meta-analysis [64] compared the effects of TIPS creation with those of endoscopic treatment with or without propranolol administration (i.e., conventional treatment) on recurrent bleeding, encephalopathy, and mortality in 948 patients.

The advantage of TIPS was a significant reduction in rebleeding (odds ratio 3.28; 95% CI 2.28–4.72). By contrast, the risk for HE was in favor of endoscopic treatment (odds ratio 0.48; 95% CI 0.34–0.67). Mortality was unchanged. Another randomized study compared TIPS with drug therapy in the prevention of rebleeding in 91 patients. Rebleeding occurred in 13% of TIPS-treated patients and in 39% of drug-treated patients. HE was more frequent in the TIPS group (38 vs. 14%), the 2-year survival was identical (72%) [65]. Therefore, TIPS creation may not be the best first-choice therapy for prevention of recurrent variceal bleeding.

Ectopic Bleeding Sites

Few studies and case reports used TIPS for the treatment of ectopic bleeding sources. Ectopic varices may be best defined as large venous collaterals occurring anywhere in the abdomen except in the cardioesophageal region. They account for up to 5% of all variceal bleeding [66]. One study compared TIPS and transcatheter sclerotherapy in the treatment of gastric varices. Transcatheter sclerotherapy provided better bleeding control than TIPS and was associated with a higher survival rate [67]. No difference was found between the pressures at which gastric varices and esophageal varices bled and TIPS was equally effective in the treatment of both esophageal and gastric hemorrhage [68]. This was true as well in an emergency situation [60]. Medical treatment with β -blockers and nitrates is ineffective [69]. TIPS was effective in the treatment of portal hypertensive gastropathy but not in gastric vascular ectasia, suggesting that portal hypertensive gastropathy and gastric vascular ectasia are different lesions [70]. Bleeding from duodenal, colonic, and rectal varices has been treated with and without failure of endoscopic treatment [71, 72]. Since randomized studies are lacking and are hard to perform, an algorithmic team approach is suggested considering patients' characteristics [66].

Ascites and Related Complications

Ascites is a common complication of cirrhosis and its development carries a significant worsening of the prognosis. Recently, the International Ascites Club has developed guidelines for the treatment of cirrhotic ascites. As extensively covered in this issue, treatment of mild to moderate ascites should be managed by salt restriction and diuretics. Gross ascites should be treated by therapeutic paracentesis followed by colloid volume expansion

Table 3. Randomized studies comparing TIPS and paracentesis (Para) or PVS

	Lebrec et al. [87] (n = 25)		Rössle et al. [88] (n = 60)		Gines et al. [89] (n = 70)		Salerno et al. [91] (n = 66)		Sanyal et al. [90] (n = 109)		Rosemurgy et al. [92] (n = 32)	
	TIPS	Para	TIPS	Para	TIPS	Para	TIPS	Para	TIPS	Para	TIPS	PVS
Response, %	83	0	79	24	3.6 ¹	11.7 ¹			58	16	80	56
HE	23	0	58	48	77	66	61	39	38	21		
<i>Survival</i>												
1 year	29	70	69	52	41	35	77	52	70	70	63	56
2 years	29	56	58	32	26	30	59	29			50	38

¹ Number of paracenteses within 1 year after treatment; HE = hepatic encephalopathy.

and diuretics [73–75]. Refractory ascites (RA) has been defined by the International Ascites Club as well [76]. To date, large volume paracentesis, the peritoneo-venous shunt (PVS) and TIPS are used for its treatment. Surgical shunts have been abandoned for the high rate of HE and liver failure [77]. Eleven nonrandomized studies suggested that TIPS is an effective treatment for RA with a response rate of 50–90%. Prevalence of HE amounted to 30%. One-year survival varied between 30 and 75% [20, 78–80]. Mobilization of ascites after TIPS may occur early or within months and is usually accompanied by improved sodium handling [81, 82]. In successful cases, nutritional status improves, possibly due to intestinal decompression and reduced protein loss and insulin resistance [20, 83–86]. Five randomized studies comparing TIPS with large volume paracentesis have been published so far (table 3) [87–91]. Overall, TIPS improved ascites in 60–83% as compared to paracentesis in 0–20%. The incidence of HE was higher in the TIPS group (23–77%) as compared to the paracentesis group (0–66%). Survival was identical in 2 studies [89, 90], in favor of paracentesis in 1 study [87]. Two studies demonstrated improved survival after TIPS [88, 91]. Estimated costs per subjects were USD 19,813 (TIPS) and USD 9,765 (paracentesis) [89]. One study compared TIPS and PVS (table 3) [92]. Both treatments controlled ascites, but TIPS was superior in the long term. Survival was identical. Irreversible shunt occlusion occurred in 19% of patients after TIPS and in 38% of patients after PVS.

Hepatic hydrothorax (HH) is a rare but severe complication of cirrhosis. Fluid accumulates in the thoracic cavity and patients have only mild or moderate ascites. Several studies showed that TIPS improves HH in 70% of cases. The 1-year survival is comparable to that of patients with RA [93–99].

Functional renal failure is another severe complication in patients with cirrhosis. Rapidly progressive deterioration of renal function has been defined as type 1 hepatorenal syndrome (HRS) with a 1-year survival of only 10%. In type 2 HRS, renal function is chronically impaired and survival is comparable with that of RA [76]. In patients with preserved liver function, TIPS is a therapeutic option, but randomized data are lacking [20, 100–103].

In conclusion, refractory ascites should be treated with large volume paracentesis followed by colloid substitution. OLT should be considered early. TIPS is recommended if the frequency of paracentesis exceeds 2–3 per month. Additional complications such as umbilical hernia, HH or type 2 HRS favour TIPS, as long as liver function is preserved (e.g. bilirubin <3.5 mg/dl, no overt HE).

Rare Indications

Budd-Chiari syndrome is the result of hepatic vein thrombosis due to various thrombogenic conditions. Budd-Chiari syndrome leads to severe alterations in the liver microcirculation, which can be reversed by TIPS (fig. 2). Patients present with fulminant, acute or chronic symptoms of liver failure [104]. Medical treatment, surgical shunts and OLT have been used as treatment. TIPS has the advantage that the shunt exits into the right atrium. Thus, compression of the inferior caval vein has no influence on shunt function. After early case reports [105, 106], larger series have been published [107–111]. These studies show excellent results on survival and control of symptoms. Early and late shunt malfunction may be reduced by the use of ePTFE stent grafts [112].

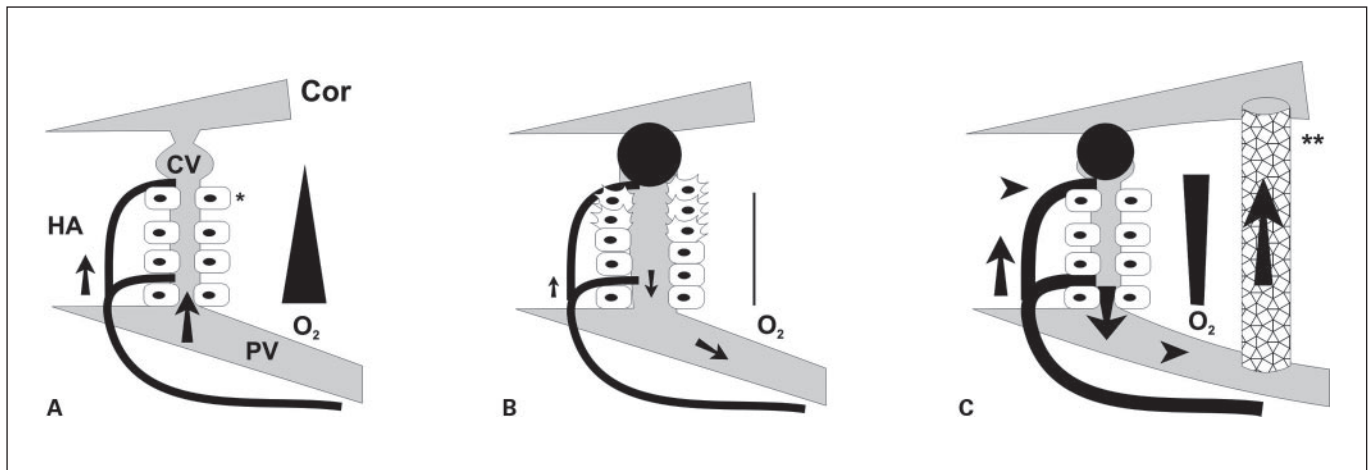


Fig. 2. Schematic representation of liver blood flow and oxygen supply in normal liver (**A**), in the Budd-Chiari syndrome (**B**), and after TIPS** (**C**). In the normal situation, portal vein flow (PV) directed to the central vein (CV) accounts for 70% of hepatocyte (*) blood supply, the hepatic artery (HA) contributes 30%. Hepatic vein thrombosis blocks portal vein flow, and high intrahepatic pressure allows only little arterial blood supply. After TIPS, portal hypertension is decompressed, and arterial blood flow increases (buffer reserve), resulting in retrograde flow through intrahepatic portal branches into the shunt (**C**).

Veno-occlusive disease is a severe complication of bone marrow transplantation. Since survival depends on the presence or absence of multi-organ failure, the outcome of TIPS was disappointing [113, 114].

TIPS has been used for the treatment of non-cavernomatous portal vein thrombosis. In about 50%, restoration of portal blood flow is possible [115–117]. Patients with hepato-pulmonary syndrome [118–120] and patients with malignant portal hypertension [121] have been successfully treated with TIPS.

TIPS does not improve early graft function after OLT, nor does it reduce blood transfusion requirements during OLT [122–124]. ePTFE-covered endoprostheses do not interfere with a later OLT [124].

In conclusion, TIPS can be regarded as the rescue treatment when medical or endoscopic treatment fails in bleeders. Large volume paracentesis is the first-line treatment for patients with RA, followed by TIPS when frequent paracenteses are needed. Despite the lack of randomized studies, TIPS seems to be the treatment of choice in patients with Budd-Chiari syndrome.

References

- 1 Palmaz JC, Sibbitt RR, Reuter SR, Garcia F, Tio FO: Expandable intrahepatic portacaval shunt stents: Early experience in the dog. *Am J Roentgenol* 1985;145:821–825.
- 2 Rösch J, Hanafee W, Snow H, Barenfus M, Gray R: Transjugular intrahepatic portacaval shunt. *Am J Surg* 1971;121:588–592.
- 3 Colapinto RF, Stronell RD, Gildiner M, et al: Formation of intrahepatic portosystemic shunts using a balloon dilatation catheter: Preliminary clinical experience. *AJR Am J Roentgenol* 1983;140:709–714.
- 4 Gutierrez OH, Burgener FA: Production of nonsurgical portosystemic venous shunts in dogs by transjugular approach. *Radiology* 1979;130:507–509.
- 5 Rössle M, Richter GM, Nöldge G, et al: Performance of an intrahepatic portacaval shunt (PCS) using a catheter technique – a case report. *Hepatology* 1988;8:1348A.
- 6 Gschwantler M, Gebauer A, Rohmoser M, et al: Clinical outcome two years after implantation of a transjugular intrahepatic portosystemic shunt for recurrent variceal bleeding (see comments). *Eur J Gastroenterol Hepatol* 1997; 9:15–20.
- 7 Rössle M, Siegerstetter V, Huber M, Ochs A: The first decade of the transjugular intrahepatic portosystemic shunt (TIPS): State of the art. *Liver* 1998;18:73–89.
- 8 Krajina A, Lojik M: TIPS Technique; in Hulek P, Krajina A (eds): *Current Practice of TIPS*. Hradec Kralove, Olga Stambergova, 2001, pp 56–119.
- 9 Haskal ZJ, Martin L, Cardella JF, et al: Quality improvement guidelines for transjugular intrahepatic portosystemic shunts. *J Vasc Interv Radiol* 2003;14:S265–S270.
- 10 Rössle M, Siegerstetter V, Olschewski M, Ochs A, Berger E, Haag K: How much reduction in portal pressure is necessary to prevent variceal rebleeding? A longitudinal study in 225 patients with transjugular intrahepatic portosystemic shunts. *Am J Gastroenterol* 2001;96: 3379–3383.

- 11 Kleber G, Steudel N, Behrmann C, et al: Hepatic arterial flow volume and reserve in patients with cirrhosis: Use of intra-arterial Doppler and adenosine infusion. *Gastroenterology* 1999;116:906–914.
- 12 Gülberg V, Haag K, Rössle M, Gerbes AL: Hepatic arterial buffer response in patients with advanced cirrhosis. *Hepatology* 2002;35:630–634.
- 13 Walser E, Ozkan OS, Raza S, Soloway R, Gajula L: Hepatic perfusion as a predictor of mortality after transjugular intrahepatic portosystemic shunt creation in patients with refractory ascites. *J Vasc Interv Radiol* 2003;14:1251–1257.
- 14 Huonker M, Schumacher YO, Ochs A, Sorichter S, Keul J, Rössle M: Cardiac function and haemodynamics in alcoholic cirrhosis and effects of the transjugular intrahepatic portosystemic shunt. *Gut* 1999;44:743–748.
- 15 Azoulay D, Castaing D, Dennison A, Martino W, Eyraud D, Bismuth H: Transjugular intrahepatic portosystemic shunt worsens the hyperdynamic circulatory state of the cirrhotic patient: Preliminary report of a prospective study. *Hepatology* 1994;19:129–132.
- 16 Stanley AJ, Redhead DN, Bouchier IA, Hayes PC: Acute effects of transjugular intrahepatic portosystemic stent-shunt (TIPSS) procedure on renal blood flow and cardiopulmonary hemodynamics in cirrhosis. *Am J Gastroenterol* 1998;93:2463–2468.
- 17 Jalan R, Forrest EH, Redhead DN, Dillon JF, Hayes PC: Reduction in renal blood flow following acute increase in the portal pressure: Evidence for the existence of a hepatorenal reflex in man? *Gut* 1997;40:664–670.
- 18 Wong F, Sniderman K, Liu P, Blendis LM: The mechanism of the initial natriuresis after transjugular intrahepatic portosystemic shunt. *Gastroenterology* 1997;112:899–907.
- 19 Wong F, Sniderman K, Liu P, Allidina Y, Sherman M, Blendis LM: Transjugular intrahepatic portosystemic stent shunt: Effects on hemodynamics and sodium homeostasis in cirrhosis and refractory ascites. *Ann Intern Med* 1995;122:816–822.
- 20 Ochs A, Rössle M, Haag K, et al: The transjugular intrahepatic portosystemic stent-shunt procedure for refractory ascites. *N Engl J Med* 1995;332:1192–1197.
- 21 Tripathi D, Helmy A, Macbeth K, et al: Ten years' follow-up of 472 patients following transjugular intrahepatic portosystemic stent-shunt insertion at a single centre. *Eur J Gastroenterol Hepatol* 2004;16:9–18.
- 22 Haag K, Ochs A, Deibert P, et al: Hemodynamics, liver function and clinical follow-up after TIPSS (German). *Radiologe* 1994;34:183–186.
- 23 Nagele T, Seeger U, Pereira P, et al: MR proton spectroscopy to monitor the concentration changes in cerebral metabolites following a TIPSS placement. *Röfo Fortschr Geb Rontgenstr Neuen Bildgeb Verfahr* 1999;170:298–303.
- 24 Hauenstein KH, Haag K, Ochs A, Langer M, Rössle M: The reducing stent: Treatment for transjugular intrahepatic portosystemic shunt-induced refractory hepatic encephalopathy and liver failure. *Radiology* 1995;194:175–179.
- 25 Rose SE, Katz MD: Intentional occlusion of a transjugular intrahepatic portosystemic shunt. *Cardiovasc Intervent Radiol* 1995;18:109–111.
- 26 Haskal ZJ, Cope C, Soulen MC, Shlansky-Goldberg RD, Baum RA, Redd DC: Intentional reversible thrombosis of transjugular intrahepatic portosystemic shunts. *Radiology* 1995;195:485–488.
- 27 Haag K, Ochs A, Hauenstein KH, Siegerstetter V, Deibert P, Rössle M: Management of TIPSS-induced refractory hepatic encephalopathy. *Hepatology* 1994;20:111A.
- 28 Mamiya Y, Kanazawa H, Kimura Y, et al: Hepatic encephalopathy after transjugular intrahepatic portosystemic shunt. *Hepatol Res* 2004;30:162–168.
- 29 Chalasani N, Clark WS, Martin LG, et al: Determinants of mortality in patients with advanced cirrhosis after transjugular intrahepatic portosystemic shunting. *Gastroenterology* 2000;118:138–144.
- 30 Brown DB, Fundakowski CE, Lisker-Melman M, et al: Comparison of MELD and Child-Pugh scores to predict survival after chemoembolization for hepatocellular carcinoma. *J Vasc Intervent Radiol* 2004;15:1209–1218.
- 31 Schepke M, Roth F, Fimmers R, et al: Comparison of MELD, Child-Pugh, and Emory model for the prediction of survival in patients undergoing transjugular intrahepatic portosystemic shunting. *Am J Gastroenterol* 2003;98:1167–1174.
- 32 Schepke M, Roth F, Koch L, et al: Prognostic impact of renal impairment and sodium imbalance in patients undergoing transjugular intrahepatic portosystemic shunting for the prevention of variceal rebleeding. *Digestion* 2003;67:146–153.
- 33 Alessandria C, Gaia S, Marzano A, Venon WD, Fadda M, Rizzetto M: Application of the model for end-stage liver disease score for transjugular intrahepatic portosystemic shunt in cirrhotic patients with refractory ascites and renal impairment. *Eur J Gastroenterol Hepatol* 2004;16:607–612.
- 34 Benito A, Bilbao J, Hernandez T, et al: Doppler ultrasound for TIPSS: Does it work? *Abdom Imaging* 2004;29:45–52.
- 35 Middleton WD, Teefey SA, Darcy MD: Doppler evaluation of transjugular intrahepatic portosystemic shunts. *Ultrasound Q* 2003;19:56–70.
- 36 Wachsberg RH: Doppler ultrasound evaluation of transjugular intrahepatic portosystemic shunt function: Pitfalls and artifacts. *Ultrasound Q* 2003;19:139–148.
- 37 Murphy TP, Beecham RP, Kim HM, Webb MS, Scola F: Long-term follow-up after TIPSS: Use of Doppler velocity criteria for detecting elevation of the portosystemic gradient. *J Vasc Interv Radiol* 1998;9:275–281.
- 38 Zizka J, Elias P, Krajina A, et al: Value of Doppler sonography in revealing transjugular intrahepatic portosystemic shunt malfunction: A 5-year experience in 216 patients. *AJR Am J Roentgenol* 2000;175:141–148.
- 39 Haag K: Color Doppler Imaging of Abdominal Vessels; in Lanzer P, Yoganathan AP (eds): *Vascular Imaging by Color Doppler and Magnetic Resonance*. Berlin, Springer, 1991, pp 241–265.
- 40 Siegerstetter V, Huber M, Ochs A, Blum HE, Rössle M: Platelet aggregation and platelet-derived growth factor inhibition for prevention of insufficiency of the transjugular intrahepatic portosystemic shunt: A randomized study comparing trapidil plus ticlopidine with heparin treatment. *Hepatology* 1999;29:33–38.
- 41 Angermayr B, Cejna M, Koenig F, et al: Survival in patients undergoing transjugular intrahepatic portosystemic shunt: ePTFE-covered stentgrafts versus bare stents. *Hepatology* 2003;38:1043–1050.
- 42 Hausegger KA, Portugaller H, Macri NP, et al: Covered stents in transjugular portosystemic shunt: healing response to non-porous ePTFE covered stent grafts with and without intraluminal irradiation. *Eur Radiol* 2003;13:1549–1558.
- 43 Cejna M, Peck-Radosavljevic M, Thurnher S, et al: ePTFE-covered stent-grafts for revision of obstructed transjugular intrahepatic portosystemic shunt. *Cardiovasc Intervent Radiol* 2002;25:365–372.
- 44 DiSalle RS, Dolmatch BL: Treatment of TIPSS stenosis with ePTFE graft-covered stents. *Cardiovasc Intervent Radiol* 1998;21:172–175.
- 45 Charon JP, Alaeddin FH, Pimpalwar SA, et al: Results of a retrospective multicenter trial of the Viatorr expanded polytetrafluoroethylene-covered stent-graft for transjugular intrahepatic portosystemic shunt creation. *J Vasc Interv Radiol* 2004;15:1219–1230.
- 46 Imperiale TF, Teran JC, McCullough AJ: A meta-analysis of somatostatin versus vasopressin in the management of acute esophageal variceal hemorrhage. *Gastroenterology* 1995;109:1289–1294.
- 47 Ioannou G, Doust J, Rockey DC: Terlipressin for acute esophageal variceal hemorrhage. *Cochrane Database Syst Rev* 2001;CD002147.
- 48 Sharara AI, Rockey DC: Gastroesophageal variceal hemorrhage. *N Engl J Med* 2001;345:669–681.
- 49 D'Amico G, Pietrosi G, Tarantino I, Pagliaro L: Emergency sclerotherapy versus vasoactive drugs for variceal bleeding in cirrhosis: A Cochrane meta-analysis. *Gastroenterology* 2003;124:1277–1291.
- 50 Avgerinos A, Armonis A, Manolakopoulos S, et al: Endoscopic sclerotherapy versus variceal ligation in the long-term management of patients with cirrhosis after variceal bleeding. A prospective randomized study. *J Hepatol* 1997;26:1034–1041.
- 51 Gross M, Schiemann U, Muhlhofer A, Zoller WG: Meta-analysis: Efficacy of therapeutic regimens in ongoing variceal bleeding. *Endoscopy* 2001;33:737–746.

- 52 Burroughs AK, McCormick PA: Prevention of variceal rebleeding. *Gastroenterol Clin North Am* 1992;21:119–147.
- 53 Technology Assessment Status Evaluation – Update: Endoscopic band ligation. November, 1996. ASGE. American Society for Gastrointestinal Endoscopy. *Gastrointest Endosc* 1998; 47:573–575.
- 54 Laine L, Cook D: Endoscopic ligation compared with sclerotherapy for treatment of esophageal variceal bleeding. A meta-analysis. *Ann Intern Med* 1995;123:280–287.
- 55 Haag K, Rössle M, Hauenstein KH, et al: Der transjuguläre intrahepatische portosystemische Stent-Shunt (TIPS) in der Notfallbehandlung der portalen Hypertension. *Intensivmedizin* 1993;30:479–483.
- 56 Le Moine O, Deviere J, Ghysels M, et al: Transjugular intrahepatic portosystemic stent shunt as a rescue treatment after sclerotherapy failure in variceal bleeding. *Scand J Gastroenterol* 1994;207(suppl):23–28.
- 57 McCormick PA, Dick R, Panagou EB, et al: Emergency transjugular intrahepatic portosystemic stent shunting as salvage treatment for uncontrolled variceal bleeding. *Br J Surg* 1994; 81:1324–1327.
- 58 Jalan R, John TG, Redhead DN, et al: A comparative study of emergency transjugular intrahepatic portosystemic stent-shunt and esophageal transection in the management of uncontrolled variceal hemorrhage (see comments). *Am J Gastroenterol* 1995;90:1932–1937.
- 59 Sanyal AJ, Freedman AM, Luketic VA, et al: Transjugular intrahepatic portosystemic shunts for patients with active variceal hemorrhage unresponsive to sclerotherapy. *Gastroenterology* 1996;111:138–146.
- 60 Chau TN, Patch D, Chan YW, Nagral A, Dick R, Burroughs AK: ‘Salvage’ transjugular intrahepatic portosystemic shunts: Gastric fundal compared with esophageal variceal bleeding. *Gastroenterology* 1998;114:981–987.
- 61 Banares R, Casado M, Rodriguez-Laiz JM, et al: Urgent transjugular intrahepatic portosystemic shunt for control of acute variceal bleeding. *Am J Gastroenterol* 1998;93:75–79.
- 62 Patch D, Nikolopoulou V, McCormick A, et al: Factors related to early mortality after transjugular intrahepatic portosystemic shunt for failed endoscopic therapy in acute variceal bleeding. *J Hepatol* 1998;28:454–460.
- 63 Rössle M, Haag K, Ochs A, et al: The transjugular intrahepatic portosystemic stent-shunt procedure for variceal bleeding. *N Engl J Med* 1994;330:165–171.
- 64 Burroughs AK, Vangeli M: Transjugular intrahepatic portosystemic shunt versus endoscopic therapy: Randomized trials for secondary prophylaxis of variceal bleeding: An updated meta-analysis. *Scand J Gastroenterol* 2002;37: 249–252.
- 65 Escorsell A, Banares R, Garcia-Pagan JC, et al: TIPS versus drug therapy in preventing variceal rebleeding in advanced cirrhosis: a randomized controlled trial. *Hepatology* 2002;35: 385–392.
- 66 Norton ID, Andrews JC, Kamath PS: Management of ectopic varices. *Hepatology* 1998;28: 1154–1158.
- 67 Ninoi T, Nakamura K, Kaminou T, et al: TIPS versus transcatheter sclerotherapy for gastric varices. *AJR Am J Roentgenol* 2004;183:369–376.
- 68 Rees CJ, Nylander DL, Thompson NP, Rose JD, Record CO, Hudson M: Do gastric and oesophageal varices bleed at different portal pressures and is TIPS an effective treatment? *Liver* 2000;20:253–256.
- 69 Wu CY, Yeh HZ, Chen GH: Pharmacologic efficacy in gastric variceal rebleeding and survival: Including multivariate analysis. *J Clin Gastroenterol* 2002;35:127–132.
- 70 Kamath PS, Lacerda M, Ahlquist DA, McKusick MA, Andrews JC, Nagorney DA: Gastric mucosal responses to intrahepatic portosystemic shunting in patients with cirrhosis. *Gastroenterology* 2000;118:905–911.
- 71 Obideen MK, Wehbi M, Ghazale A, Martinez E, Cai Q: Efficacy and safety of transjugular intrahepatic portosystemic shunt in the treatment of nongastric extraesophageal variceal bleeding. *J Clin Gastroenterol* 2004;38:373–376.
- 72 Illuminati G, Smail A, Azoulay D, Castaing D, Bismuth H: Association of transjugular intrahepatic portosystemic shunt with embolization in the treatment of bleeding duodenal varix refractory to sclerotherapy. *Dig Surg* 2000; 17:398–400.
- 73 Runyon BA: Care of patients with ascites. *N Engl J Med* 1994;330:337–342.
- 74 Gines P, Cardenas A, Arroyo V, Rodes J: Management of cirrhosis and ascites. *N Engl J Med* 2004;350:1646–1654.
- 75 Moore KP, Wong F, Gines P, et al: The management of ascites in cirrhosis: Report on the consensus conference of the International Ascites Club. *Hepatology* 2003;38:258–266.
- 76 Arroyo V, Gines P, Gerbes AL, et al: Definition and diagnostic criteria of refractory ascites and hepatorenal syndrome in cirrhosis (review). *International Ascites Club. Hepatology* 1996;23: 164–176.
- 77 Runyon BA: Historical aspects of treatment of patients with cirrhosis and ascites. *Semin Liver Dis* 1997;17:163–173.
- 78 Ochs A, Siegerstetter V: TIPS and refractory ascites, hepatorenal syndrome and other complications; in Hulek P, Krajina A (eds): *Current Practice of TIPS*. Hradec Kralove, Olga Stamborgova 2001, pp 133–142.
- 79 Peron JM, Barange K, Otal P, et al: Transjugular intrahepatic portosystemic shunts in the treatment of refractory ascites: Results in 48 consecutive patients. *J Vasc Intervent Radiol* 2000;11:1211–1216.
- 80 Nair S, Singh R, Yoselewitz M: Correlation between portal/hepatic vein gradient and response to transjugular intrahepatic portosystemic shunt creation in refractory ascites. *J Vasc Intervent Radiol* 2004;15:1431–1434.
- 81 Wong W, Liu P, Blendis LM, Wong F: Long-term renal sodium handling in patients with cirrhosis treated with transjugular intrahepatic portosystemic shunts for refractory ascites. *Am J Med* 1999;106:315–322.
- 82 Jalan R, Redhead DN, Thomas HW, et al: Mechanisms of changes in renal handling of sodium following transjugular intrahepatic portal systemic stent-shunt (TIPSS). *Eur J Gastroenterol Hepatol* 1996;8:1111–1116.
- 83 Plauth M, Schutz T, Buckendahl DP, et al: Weight gain after transjugular intrahepatic portosystemic shunt is associated with improvement in body composition in malnourished patients with cirrhosis and hypermetabolism. *J Hepatol* 2004;40:228–233.
- 84 Sandokji AM, Chau J, Aghdassi E, Wong F, Blendis LM, Allard JP: Effects of transjugular intrahepatic portosystemic shunt (TIPS) on nutritional status and comparison between methods of measuring fat free mass (FFM) in patients with liver cirrhosis. *Gastroenterology* 1997;112:A903.
- 85 Scheib SA, Caldwell SH, Driscoll CJ, et al: Improvement in nutritional parameters and Child-Pugh class after TIPS for refractory ascites. *Hepatology* 1996;24:574A.
- 86 Allard JP, Chau J, Sandokji K, Blendis LM, Wong F: Effects of ascites resolution after successful TIPS on nutrition in cirrhotic patients with refractory ascites. *Am J Gastroenterol* 2001;96:2442–2447.
- 87 Lebrec D, Giuily N, Hadengue A, et al: Transjugular intrahepatic portosystemic shunts – comparison with paracentesis in patients with cirrhosis and refractory ascites – a randomized trial. *J Hepatol* 1996;25:135–144.
- 88 Rössle M, Ochs A, Gülberg V, et al: A comparison of paracentesis and transjugular intrahepatic portosystemic shunting in patients with ascites. *N Engl J Med* 2000;342:1701–1707.
- 89 Gines P, Uriz J, Calahorra B, et al: Transjugular intrahepatic portosystemic shunting versus paracentesis plus albumin for refractory ascites in cirrhosis. *Gastroenterology* 2002;123:1839–1847.
- 90 Sanyal AJ, Genning C, Reddy KR, et al: The North American Study for the Treatment of Refractory Ascites. *Gastroenterology* 2003; 124:634–641.
- 91 Salerno F, Merli M, Riggio O, et al: Randomized controlled study of TIPS versus paracentesis plus albumin in cirrhosis with severe ascites. *Hepatology* 2004;40:629–635.
- 92 Rosemurgy AS, Zervos EE, Clark WC, et al: TIPS versus peritoneovenous shunt in the treatment of medically intractable ascites: A prospective randomized trial. *Ann Surg* 2004; 239:883–889.
- 93 Siegerstetter V, Deibert P, Ochs A, Olschewski M, Blum HE, Rössle M: Treatment of refractory hepatic hydrothorax with transjugular intrahepatic portosystemic shunt: long-term results in 40 patients. *Eur J Gastroenterol Hepatol* 2001;13:529–534.

- 94 Gordon FD, Anastopoulos HT, Crenshaw W, et al: The successful treatment of symptomatic, refractory hepatic hydrothorax with transjugular intrahepatic portosystemic shunt. *Hepatology* 1997;25:1366–1369.
- 95 Nolte W, Figulla HR, Ringe B, et al: Refractory hydrothorax in primary biliary cirrhosis – successful treatment with a transjugular intrahepatic portosystemic shunt. *Dtsch Med Wochenschr* 1997;122:1275–1280.
- 96 Petruff CA, Anastopoulos HT, Chopra S, McEniff N, Lewis WD: The successful use of TIPS for the treatment of symptomatic refractory hepatic hydrothorax: long-term follow up. *Hepatology* 1996;24:190A.
- 97 Andrade RJ, Martin-Palanca A, Fraile JM, et al: Transjugular intrahepatic portosystemic shunt for the management of hepatic hydrothorax in the absence of ascites. *J Clin Gastroenterol* 1996;22:305–307.
- 98 Strauss RM, Martin LG, Kaufman SL, Boyer TD: Transjugular intrahepatic portal systemic shunt for the management of symptomatic cirrhotic hydrothorax. *Am J Gastroenterol* 1994;89:1520–1522.
- 99 Haskal ZJ, Zuckerman J: Resolution of hepatic hydrothorax after transjugular intrahepatic portosystemic shunt (TIPS) placement. *Chest* 1994;106:1293–1295.
- 100 Angeli P: Review article: prognosis of hepatorenal syndrome – has it changed with current practice? *Aliment Pharmacol Ther* 2004; 20(suppl 3):44–46.
- 101 Wong F, Pantea L, Sniderman K: Midodrine, octreotide, albumin, and TIPS in selected patients with cirrhosis and type 1 hepatorenal syndrome. *Hepatology* 2004;40:55–64.
- 102 Gines P, Guevara M, Perez-Villa F: Management of hepatorenal syndrome: another piece of the puzzle. *Hepatology* 2004;40:16–18.
- 103 Brensing KA, Textor J, Strunk H, Klehr HU, Schild H, Sauerbruch T: Transjugular intrahepatic portosystemic stent-shunt for hepatorenal syndrome [letter]. *Lancet* 1997;349: 697–698.
- 104 Cardenas A: The Budd-Chiari syndrome. *N Engl J Med* 2004;350:1906–1908.
- 105 Ochs A, Sellinger M, Haag K, et al: Transjugular intrahepatic portosystemic stent-shunt (TIPS) in the treatment of Budd-Chiari syndrome. *J Hepatol* 1993;18:217–225.
- 106 Peltzer MY, Ring EJ, LaBerge JM, Haskal ZJ, Radosevich PM, Gordon RL: Treatment of Budd-Chiari syndrome with a transjugular intrahepatic portosystemic shunt. *J Vasc Interv Radiol* 1993;4:263–267.
- 107 Rössle M, Olschewski M, Siegerstetter V, Berger E, Kurz K, Grandt D: The Budd-Chiari syndrome: outcome after treatment with the transjugular intrahepatic portosystemic shunt. *Surgery* 2004;135:394–403.
- 108 Blokzijl H, de Knegt RJ: Long-term effect of treatment of acute Budd-Chiari syndrome with a transjugular intrahepatic portosystemic shunt. *Hepatology* 2002;35:1551–1552.
- 109 Gasparini D, Del FM, Sponza M, et al: Transjugular intrahepatic portosystemic shunt by direct transcaval approach in patients with acute and hyperacute Budd-Chiari syndrome. *Eur J Gastroenterol Hepatol* 2002; 14:567–571.
- 110 Perello A, Garcia-Pagan JC, Gilabert R, et al: TIPS is a useful long-term derivative therapy for patients with Budd-Chiari syndrome uncontrolled by medical therapy. *Hepatology* 2002;35:132–139.
- 111 Blum U, Rössle M, Haag K, et al: Budd-Chiari Syndrome – technical, hemodynamic, and clinical results of treatment with transjugular intrahepatic portosystemic shunt. *Radiology* 1995;197:805–811.
- 112 Hernandez-Guerra M, Turnes J, Rubinstein P, et al: PTFE-covered stents improve TIPS patency in Budd-Chiari syndrome. *Hepatology* 2004;40:1197–1202.
- 113 Fried MW, Connaghan DG, Sharma S, et al: Transjugular intrahepatic portosystemic shunt for the management of severe venoocclusive disease following bone marrow transplantation. *Hepatology* 1996;24:588–591.
- 114 Zenz T, Rössle M, Bertz H, Siegerstetter V, Ochs A, Finke J: Severe veno-occlusive disease after allogeneic bone marrow or peripheral stem cell transplantation – role of transjugular intrahepatic portosystemic shunt (TIPS). *Liver* 2001;21:31–36.
- 115 Blum U, Haag K, Rössle M, et al: Noncavernomatous portal vein thrombosis in hepatic cirrhosis – treatment with transjugular intrahepatic portosystemic shunt and local thrombolysis. *Radiology* 1995;195:153–157.
- 116 Bilbao JI, Elorz M, Vivas I, Martinez-Cuesta A, Bastarrika G, Benito A: Transjugular intrahepatic portosystemic shunt (TIPS) in the treatment of venous symptomatic chronic portal thrombosis in non-cirrhotic patients. *Cardiovasc Intervent Radiol* 2004;27:474–480.
- 117 Cherukuri R, Haskal ZJ, Naji A, Shaked A: Percutaneous thrombolysis and stent placement for the treatment of portal vein thrombosis after liver transplantation: long-term follow-up. *Transplantation* 1998;65:1124–1126.
- 118 Selim KM, Akriviadis EA, Zuckerman E, Chen D, Reynolds TB: Transjugular intrahepatic portosystemic shunt: a successful treatment for hepatopulmonary syndrome. *Am J Gastroenterol* 1998;93:455–458.
- 119 Allgaier HP, Haag K, Ochs A, et al: Hepatopulmonary syndrome – successful treatment by transjugular intrahepatic portosystemic stent-shunt (TIPS). *J Hepatol* 1995;23:102.
- 120 Krowka MJ: Hepatopulmonary syndrome: what are we learning from interventional radiology, liver transplantation, and other disorders? *Gastroenterology* 1995;109:1009–1013.
- 121 Burger JA, Ochs A, Wirth K, et al: The transjugular stent implantation for the treatment of malignant portal and hepatic vein obstruction in cancer patients. *Ann Oncol* 1997;8: 200–202.
- 122 Gimson AE: Transjugular intrahepatic portosystemic stent-shunt and liver transplantation – how safe is the bridge? *Eur J Gastroenterol Hepatol* 2002;14:821–822.
- 123 Tripathi D, Therapondos G, Redhead DN, Madhavan KK, Hayes PC: Transjugular intrahepatic portosystemic stent-shunt and its effects on orthotopic liver transplantation. *Eur J Gastroenterol Hepatol* 2002;14:827–832.
- 124 Maleux G, Pirenne J, Vaninbroux J, Aerts R, Nevens F: Are TIPS stent-grafts a contraindication for future liver transplantation? *Cardiovasc Intervent Radiol* 2004;27:140–142.