

Diverticular Disease in the Elderly

Giuseppe Comparato^a Alberto Pilotto^b Angelo Franzè^c Marilisa Franceschi^{a, b}
Francesco Di Mario^a

^aChair of Gastroenterology, University of Parma, Parma, ^bDepartment of Geriatrics, Casa Sollievo della Sofferenza, Istituto di Ricovero e Cura a Carattere Scientifico, San Giovanni Rotondo, and ^cGastroenterology and Endoscopy Unit, Azienda Ospedaliera, Parma, Italy

Key Words

Colonic diverticula, causes · Diverticular disease, elderly · Diverticulitis · Diverticulitis, diagnosis · Diverticular colitis, pathogenesis · Diverticulosis, definitions and epidemiology

Abstract

There are few diseases whose incidence varies as greatly worldwide as that of diverticulosis. Its prevalence is largely age-dependent: the disease is uncommon in those under the age of 40, the prevalence of which is estimated at approximately 5%; this increases to 65% in those ≥ 65 years of age. Of patients with diverticula, 80–85% remain asymptomatic, while, for unknown reasons, only three-fourths of the remaining 15–20% of patients develop symptomatic diverticular disease. Traditional concepts regarding the causes of colonic diverticula include alterations in colonic wall resistance, disordered colonic motility and dietary fiber deficiency. Currently, inflammation has been proposed to play a role in diverticular disease. Goals of therapy in diverticular disease should include improvement of symptoms and prevention of recurrent attacks in symptomatic, uncomplicated diverticular disease, and prevention of the complications of disease such as diverticulitis. Diverticulitis is the most usual clinical complication of diverticular disease, affecting 10–25% of patients with diverticula. Most patients admitted with acute diverticulitis respond to conservative treatment, but 15–30% require surgery. Predictive factors for severe diverticulitis are sex, obesity, immunodeficiency and old age.

Surgery for acute complications of diverticular disease of the sigmoid colon carries significant rates of morbidity and mortality, the latter of which occurs predominantly in cases of severe comorbidity. Postoperative mortality and morbidity are to a large extent driven by patient-related factors.

Copyright © 2007 S. Karger AG, Basel

Definitions and Epidemiology

Diverticulosis of the colon is an acquired condition that results from herniation of the mucosa through defects in the muscle layer [1]. There are few diseases whose incidence varies as greatly as that of diverticulosis [2]. The true prevalence of diverticulosis is difficult to define since most individuals are asymptomatic [3]. Diverticular disease is found commonly in developed countries. It is now widely accepted that chronic diverticular formation occurs in westernized societies due to a lack of fiber in the diet [4]. The prevalence is largely age-dependent, as it is uncommon in those under the age of 40, in whom the prevalence is estimated at approximately 5%; this increases to 65% in those ≥ 65 years of age (fig. 1) [5–7]. Of patients with diverticula, 80–85% remain asymptomatic, while, for unknown reasons, only three-fourths of the remaining 15–20% of patients develop symptomatic diverticular disease. These patients have some symptoms but no signs of inflammation [8]. The remaining one-fourth, or approximately 5% of all patients with diverticula, develops diverticulitis and a small number develop compli-

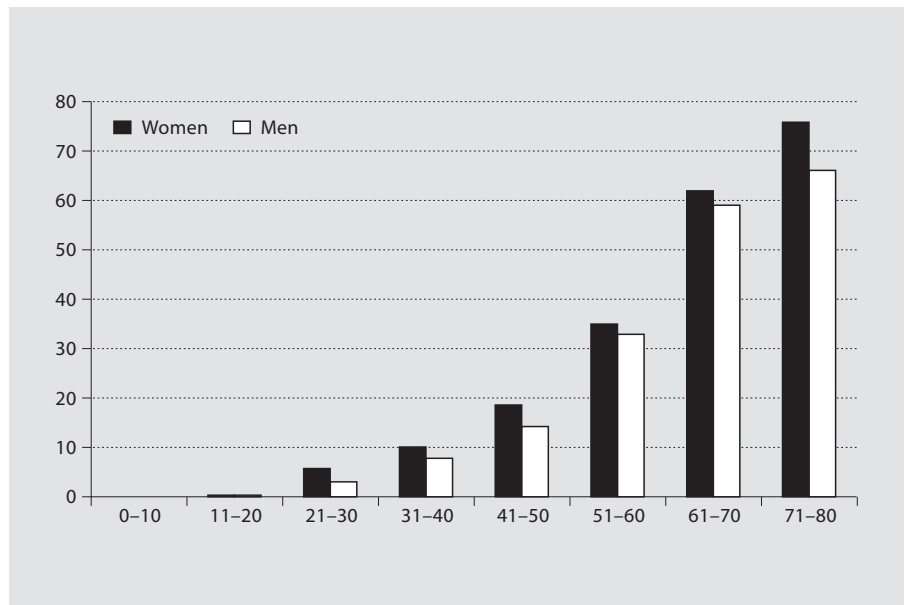


Fig. 1. Prevalence of diverticulosis for age according to age.

cations of diverticulitis such as abscess formation, fistulas, obstruction, or hemorrhage [9].

Diverticular disease should be classified as [10]: (1) *symptomatic uncomplicated diverticular disease*: single episode of non-specific symptoms, such as lower discomfort or abdominal pain, bloating, abdominal tenderness, constipation, diarrhea without any sign of inflammation (fever, neutrophilia, phlogosis of diverticula); (2) *recurrent symptomatic uncomplicated diverticular disease*: more than one attack per year of non-specific symptoms without signs of inflammation, or (3) *complicated diverticular disease*: abdominal symptoms associated with signs of inflammation.

Causes and Pathogenesis

Colonic diverticula typically form in parallel rows between the taeniae coli because of weakness of the muscle wall at sites of penetration of the vasa recta supplying the mucosa. In European and US populations, diverticula arise mainly in the distal colon, with 90% of patients having sigmoid colon involvement and only 15% having right-sided diverticula [7, 11–13].

Traditional concepts regarding the causes of colonic diverticula include alterations in colonic wall resistance, disordered colonic motility, and dietary deficiencies, especially of fibers [14, 15]. Presently, inflammation has been proposed to play a role in diverticular disease [16].

Pathological evidence shows that patients with symptomatic diverticular disease often exhibit microscopic inflammation of the mucosa close to diverticula [16]. Experienced colonoscopists sometimes encounter endoscopic findings of diverticular inflammation in patients without clinical evidence of acute diverticulitis. Endoscopic findings included erythema and edema of a diverticular opening, pus emanating from a diverticular orifice, and a polypoid mass of granulation tissue in a diverticular orifice [17]. Whether this inflammation is the actual focus of the diverticular disease remains unclear.

In some cases, there may even be extensive inflammation, which is defined as diverticular colitis [18]. Most of these patients are over age 60 and present on endoscopic examination a segment of active inflammation in the sigmoid colon in an area of multiple diverticula causing hematochezia, altered bowel function, and abdominal pain. Endoscopy reveals areas of patchy mucosal hemorrhage granularity and exudate without gross ulceration adjacent to multiple diverticular orifices. Endoscopic biopsies confirm focal chronic active colitis without granulomas [19].

To date, the pathogenesis of diverticular colitis is unknown and its relation to the diverticula is unclear. Postulates include mucosal prolapse, relative ischemia, bacterial overgrowth, increased exposure to intraluminal toxins and antigens secondary to fecal stasis [19, 20]. Some of these factors are similar to those implicated in the pathogenesis of inflammatory bowel disease (IBD)

and this colitis may be considered a 'bridge' disease between classic IBD and diverticulitis [21].

There is also evidence that diverticular disease may be based on a disorder of the enteric nervous system, which may, in turn, be caused by an inflammatory process.

Diagnosis

For years, barium enema was the standard investigation in diverticulosis patients, and although it provides information on the number and location of colonic diverticula, it cannot discern their clinical relevance. Inaccurate findings have been reported in nearly a third of patients with diverticulosis [22]. This disorder has, in the past, been regarded as a contraindication to colonoscopy for fear of causing a perforation [23, 24]. Further data and extensive clinical experience have shown that colonoscopy is safe in this population, although the diverticular colon can be difficult to examine because of spasm, luminal narrowing, and fixation.

Therapy

Goals of therapy in diverticular disease should be improvement of symptoms and prevention of recurrent attacks in symptomatic uncomplicated diverticular disease, and prevention of the complications of disease such as diverticulitis [16].

Up until now several therapies have been proposed, including: high-fiber diet and/or fiber supplementation; spasmolytics; probiotics; antibiotics, and mesalazine (5-ASA).

A significant inverse association has been reported between dietary fiber intake and risk of development of clinically evident diverticular disease. Insoluble fiber from fruits and vegetables was noted to be more protective than cereal fibers [25]. These results provide support for a recommendation that patients with asymptomatic diverticular disease might benefit from increasing their fruit and vegetable fiber intake. Several uncontrolled studies suggest that fiber supplementation benefits patients with symptomatic diverticular disease [25], but no large placebo-controlled trials have been performed. Nevertheless, a high-fiber diet, fiber supplementation, or both are generally recommended and are likely to do no harm.

Similarly, no evidence supports the use of antispasmodic agents, despite the cramping and bloating often

associated with symptomatic diverticular disease [9]. The role of probiotics in the treatment of diverticular disease remains unclear. To date there is only one study that reports an improvement in symptoms in patients with non-complicated diverticular disease after treatment with *Escherichia coli* Nissle [26].

Rifaximin, a broad-spectrum, poorly absorbed antibiotic, and more recently, mesalazine, appear to be of some advantage in obtaining symptom relief in uncomplicated diverticular disease, and in reducing the incidence of the primary complications of this disease [27, 28]. The rationale for antibiotic therapy in these patients involves the role of intestinal microflora in determining symptoms by fiber degradation and gas production [29]. Mesalazine is widely and effectively used for the treatment of IBD. Inflammation seems to play an important pathogenic role in diverticulitis, diverticular disease-associated chronic colitis and symptomatic uncomplicated diverticular disease [18, 20, 30]. Inflammation in such diseases seems to be generated by a heightened production of proinflammatory cytokines, reduction in anti-inflammatory cytokines, and enhanced intramucosal synthesis of nitric oxide.

The use of mesalazine in the treatment of such diseases is advisable based on its anti-inflammatory properties, as it can reduce mucosal hyperemia, edema, erosion and other inflammatory signs observed near and often well away from the diverticular orifices themselves [18–20, 30]. Several studies showed promising results of mesalazine in the prevention and treatment of symptoms in symptomatic uncomplicated disease [31–34].

Complications

Diverticulitis

Diverticulitis is the most usual clinical complication of diverticular disease, affecting 10–25% of patients with diverticula [7]. Diverticulitis is the result of a micro- or macroperforation of a diverticulum, due to erosion of the luminal wall by increased intraluminal pressure or thickened fecal material in the neck of diverticulum. Microperforations can be contained by pericolic fat and mesentery causing small pericolic abscesses. Macroperforations can result in an extensive abscess, which can continue around the bowel wall and form a large inflammatory mass or extend to other organs. Free perforation into the peritoneum causes peritonitis [8].

Diverticulitis is characterized by acute, constant or intermittent abdominal pain most often occurring in the

Table 1. Diverticulitis and differential diagnosis

Differential diagnosis	Scenarios and diagnostic considerations
Acute appendicitis	Suspect if RLQ symptoms or non-resolution with medical therapy
Crohn's disease	Suspect if aphthous ulcers, perianal involvement, or chronic diarrhea
Colonic carcinoma	Suspect if weight loss, bleeding. Diagnose with colonic evaluation after acute inflammation resolved
Ischemic colitis	Suspect if high-risk patient, bloody diarrhea, or thumbprinting. Diagnose with limited flexible sigmoidoscopy
Pseudomembranous colitis	Suspect with antibiotic use. Diagnose with stool toxin or limited flexible sigmoidoscopy
Complicated ulcer disease	Suspect if pneumoperitoneum or peritonitis, or with clinical history, NSAID use, or dyspepsia
Ovarian cyst, abscess, torsion	Suspect in female patient with unilateral pain. Diagnose with pelvic or transvaginal ultrasound
Ectopic pregnancy	Suspect in female patient of childbearing age. Diagnose with pregnancy test and ultrasound

left lower quadrant and is sometimes associated with a change in bowel habits. Hematochezia is rare, although anorexia, nausea and vomiting can arise. Fever and leukocytosis are generally present. Some patients may complain of dysuria and frequency that are induced by bladder irritation from the adjacent inflamed colon [8]. On physical examination, localized tenderness is generally found in the left lower quadrant and may be associated with guarding and rebound tenderness; bowel sounds are often decreased but may be normal early in the condition or increased in the presence of obstruction [15]. Several conditions should be excluded in its differential diagnosis (table 1). Elderly people with diverticulosis are also at risk for ischemic colitis. Features helpful in its differential diagnosis include the presence of thumbprinting on abdominal radiographs and hematochezia, both suggestive of ischemia. Clinical signs and symptoms are often sufficient to justify a clinical diagnosis; laboratory studies (the white blood cell count is usually elevated with predominance of polymorphonuclear cells) and imaging can be used to confirm diagnosis.

Table 2 shows the imaging examinations commonly used to confirm diagnosis. CT with intravenous and oral contrast is the test of choice to confirm a suspected diagnosis of diverticulitis [35–38]. Criteria suggestive of diverticulitis include pericolic infiltration of fatty tissue, colonic wall thickening and abscess formation.

Need for admission is the initial decision to be made in uncomplicated diverticulitis. The following parameters should be considered in making this decision [8, 15]: patient's presentation; ability to tolerate oral intake; comorbidity, and adequate outpatient support. Based on these criteria, elderly patients have a high probability of needing hospital admission for adequate treatment. Figure 2a, b illustrates a decision-making flow chart for appropriate treatment.

In patients with uncomplicated diverticulitis who are clinically stable and able to tolerate fluids, outpatient treatment with broad-spectrum antibiotics covering anaerobes and Gram-negative rods for 7–10 days (table 3) and a clear liquid diet is adequate. Patients should improve within 48–72 h, at which time solid foods may be introduced very cautiously [8, 15].

Close follow-up is considered very important: if the patient experiences increasing pain, fever or an inability to tolerate fluid intake, hospitalization is appropriate. Hospitalization is recommended if patients show signs of significant inflammation, are unable to take oral fluid, are >75 years of age, or have significant comorbidity: these characteristics are in fact present in most elderly. These patients need intravenous antibiotics (table 3) and should have clear liquids or nothing by mouth and intravenous liquid. Improvement of symptoms should be expected within 2–4 days, at which point a solid diet can be

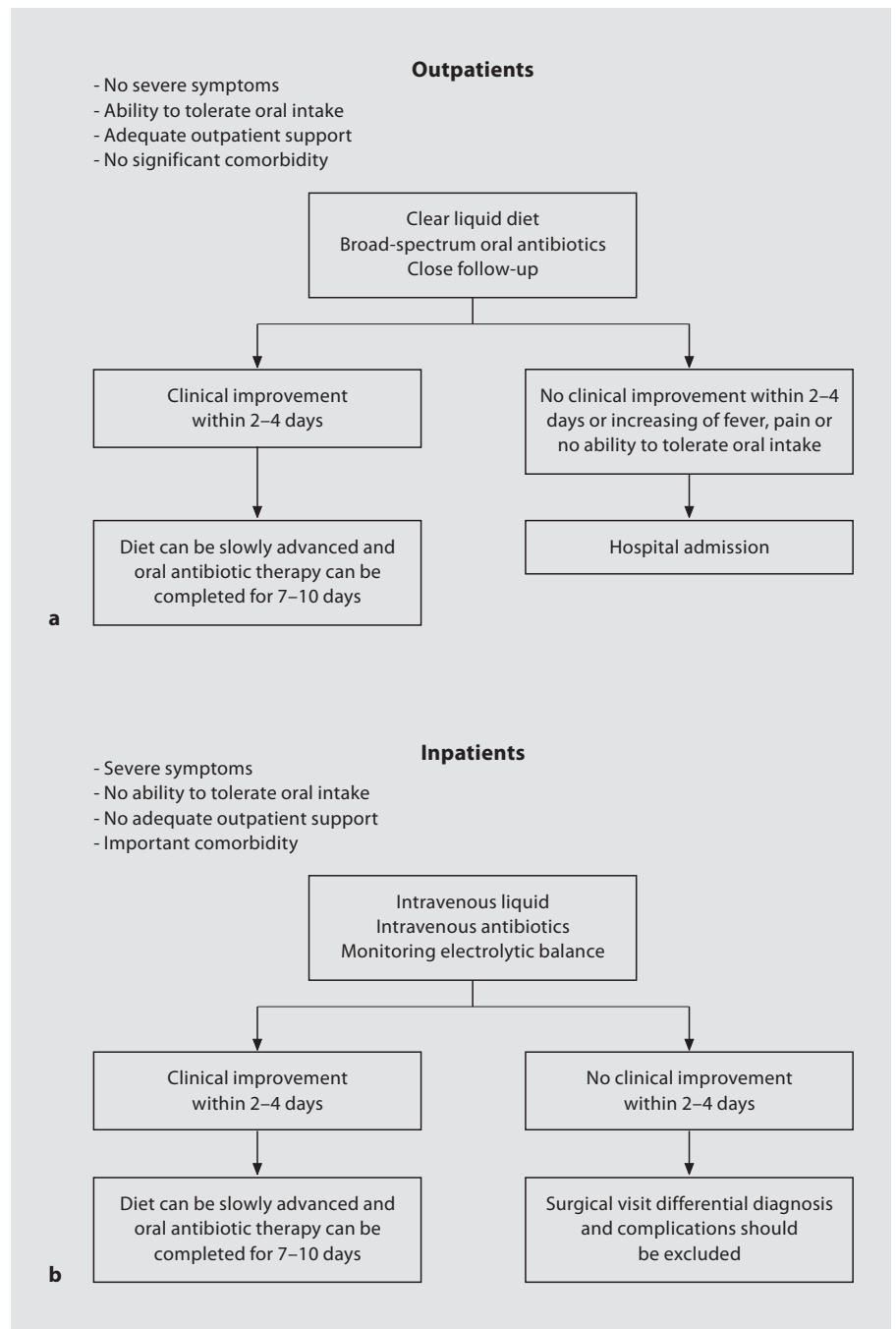


Fig. 2. Treatment of diverticulitis in outpatients (a) and inpatients (b).

slowly and carefully introduced. If improvement continues, patients may be discharged to complete a 7- to 10-day oral antibiotics course [8, 15].

Most patients admitted with acute diverticulitis respond to conservative treatment, but 15–30% require surgery [11, 39, 40]. For most patients who respond well to conservative treatment, an important clinical question

subsequently involves the likelihood of recurrence and the role of prophylactic surgical resection. The risk of recurrent symptoms after an attack of acute diverticulitis has been reported to be between 7 and 45%; a third of the patients is a reasonable approximation [11, 39, 40]. Recurrent attacks are less likely to respond to medical treatment and have a high mortality rate [39, 40], thus, most

Table 2. Diagnostic modalities in diverticulitis

CT	CT scanning has an increasing role in diagnosis, and should be regarded as the diagnostic procedure of choice. Abdominal and pelvic scanning is done with intravenous, oral, and rectal contrast. Criteria suggestive of diverticulitis include pericolic infiltration of fatty tissue, colonic wall thickening, and abscess formation. In many trials comparing CT with barium enema in suspected diverticulitis, sensitivities for CT of 93–98% and specificities of 75–100% have been consistently reported: results significantly more accurate than contrast enemas
Barium enema	Contrast enemas – once the diagnostic standard – are limited by the fact that diverticulitis is mainly an extraluminal process. If they are to be undertaken, water-soluble contrast material should be used and a low-pressure single-contrast study done. Findings deemed highly suggestive of diverticulitis include extravasated contrast material outlining an abscess cavity, intramural sinus tract, or fistula (fig. 2) [9, 46]. Absence of any diverticula should provoke reconsideration of the diagnosis. In retrospective analyses, contrast enema has been shown to have a sensitivity of 62–94%, with false-negative results in 2–15% [47, 48]
Colonscopy	Because of risk of perforation from either the device or air insufflation, endoscopy is generally avoided in initial assessment of the patient with acute diverticulitis. Its use should be restricted to situations in which diagnosis of diverticulitis is unclear. In such cases, limited sigmoidoscopy with minimum insufflation can be helpful to exclude other diagnoses, such as inflammatory, infectious, or ischemic colitis
Abdominal and chest radiographs	Chest and abdominal radiographs should generally be done in patients with clinically significant abdominal pain. A chest radiograph taken while the patient is upright can aid detection of pneumoperitoneum and help to assess cardiopulmonary status. Abdominal radiographs can show abnormal findings in 30–50% of patients which include small or large bowel dilation

authorities agree that elective resection is indicated after two attacks of uncomplicated diverticulitis [41–43]. The risk-benefit analysis of such an approach must be tailored with consideration of severity and responsiveness of the episode, general health of the patient, and risk of subsequent occurrence. Risk of resection is an evolving factor, with reports of increasingly favorable experiences with laparoscopic resections for diverticular disease [44–49]. This approach might reduce the threshold for resection

Table 3. Antibiotic treatment for patients with diverticulitis

Outpatients	Amoxicillin-clavulanate (Augmentin) Trimethoprim-sulfamethoxazole (Bactrim, Septra) and metronidazole (Flagyl) Fluoroquinolone and metronidazole
Inpatients	Metronidazole or clindamycin (Cleocin) <i>plus</i> Aminoglycoside (gentamicin [Garamycin] or tobramycin [Tobrex]) <i>or</i> Monobactam (aztreonam [Azactam]) <i>or</i> Third-generation cephalosporin (ceftriaxone [Rocephin], ceftazidime [Fortaz], cefotaxime [Claforan]) <i>alternatively</i> Second-generation cephalosporin (cefoxitin [Mefoxin], cefotetan [Cefotan]) β-Lactamase inhibitor combinations (ampicillin-sulbactam [Unasyn], ticarcillin-clavulanate [Timentin])

in some patients by lowering operative morbidity. However, some patients will still have symptoms after surgical resection. Surgery for acute complications of diverticular disease of the sigmoid colon carries a high morbidity rate and a substantial mortality rate. The majority of deceased patients have severe comorbidity. Postoperative mortality and morbidity are to a large extent driven by patient-related factors [50].

Predictive factors of severity in diverticulitis are sex, obesity, immunodeficiency and age. Disease seems to be more virulent in people younger than 40 years old versus elderly patients: 66–88% of these necessitate urgent surgery during their initial attack with a high risk of recurrences of complications [11, 51–53]. For these reasons, and because of the low risk of an elective procedure in otherwise healthy young patients, resection generally is indicated after one well-documented episode of uncomplicated diverticulitis [39, 41]. Some authors do not agree with this strategy [54, 55].

Complications of diverticulitis include abscess, fistula, bowel obstruction and free perforation. These complications all require surgical consultation. Abscesses occur when the pericolic tissues fail to control the spread of the inflammatory process. Abscess formation should be suspected when fever, leukocytosis, or both persist despite an adequate trial of appropriate antibiotics. A tender mass may be palpable on physical examination. Right up-

per quadrant pain or elevated transaminase levels may be evidence for a pyogenic liver abscess. CT-guided percutaneous drainage may be appropriate for small abscesses or while patients with sepsis are being stabilized for surgery [29, 54].

Peridiverticular abscesses can progress to form fistulas between the colon and surrounding structures in up to 10% of patients. Colovesical fistulas are the most common variety and require surgery for treatment. Fistulas involving the bladder are more common in men; in women, the uterus is interposed between the colon and the bladder.

Intestinal obstruction is uncommon in diverticulitis, occurring in approximately 2% of patients. The small bowel is affected most often, and obstruction usually is caused by adhesions. The colon can become obstructed because of luminal narrowing caused by inflammation or compression by an abscess. Multiple attacks can lead to progressive fibrosis and stricture of the colonic wall. Obstruction is generally self-limiting and responds to conservative therapy. If persistent, obstruction of the colon can be treated by a variety of endoscopic and surgical techniques.

Free perforation with peritonitis is rare, but it carries a mortality rate as high as 35% and requires urgent surgical consultation. If generalized peritonitis develops, the mortality rate is even higher. Perforation has been linked to non-steroidal anti-inflammatory drug (NSAID) use in case-control studies [56]. Glucocorticoids may increase this risk. Steroids also may mask symptoms and delay appropriate therapy. Because of this, NSAIDs and glucocorticoids should be used with caution in patients who have known diverticular disease. Mitchell and Shaheen [57] recently concluded that there is a protective association between calcium channel blockers and perforated colonic diverticular disease. Therefore, elderly patients with hypertension and diverticulosis should be preferably prescribed calcium channel blockers for antihypertensive therapy.

Hemorrhage

Significant lower gastrointestinal bleeding can be caused by diverticula, vascular ectasias, colitis, or neoplasms [58–60]. Diverticular sources have been reported to be the most typically identified cause, accounting for >40% of lower gastrointestinal bleeding episodes [61, 62]. Severe hemorrhage can arise in 3–5% of patients with diverticulosis [63, 64]. Despite the fact that most diverticula are in the left colon in subjects from developed Western countries, the site of bleeding may more often be located

in the proximal colon [63, 65–68]. Microangiography on resected specimens from patients with bleeding diverticula shows intimal thickening and medial thinning of the vasa recta as it courses over the dome of the diverticulum [65]. These changes arise asymmetrically towards the lumen and lead to segmental weakening of the artery, predisposing to rupture. Factors that initiate this arterial change are unknown, although inflammation does not seem to be a contributing factor. This finding confirms the clinical impression that bleeding rarely complicates diverticulitis. A recent study demonstrated that diverticular hemorrhage is associated with atherosclerosis and ageing: this might explain why diverticulosis is a frequent cause of bleeding in elderly vasculopathic patients.

The association of use of NSAIDs with ulcer disease and upper gastrointestinal bleeding is well documented, but data have also implicated these drugs in diverticular bleeding. In a large prospective series of patients with lower gastrointestinal bleeding (of whom 50% were diverticular), a bleeding risk with NSAIDs was reported that was equal to that of duodenal ulcer [69]. In the Health Professionals Follow-Up Study [70], regular NSAID use was associated with an increased risk of diverticular bleeding. Whether patients with diverticulosis should be advised to avoid NSAIDs, as is done for ulcer patients, or use COX2-selective agents, is still not clear.

Clinical presentation of diverticular hemorrhage is usually one of an abrupt painless onset. The patient can have mild lower abdominal cramps or the urge to defecate, followed by passage of voluminous red or maroon blood or clots. While melena can sometimes occur with a slowly bleeding right colon lesion, the arterial nature of diverticular bleeding makes this presentation uncommon. Presence of colonic diverticula should not be judged an adequate explanation for a positive fecal occult blood test or as a cause of iron deficiency anemia. Hemorrhage ceases spontaneously in 70–80% of patients, and rebleeding rates range from 22 to 38% [63, 64, 67]. The chance of a third bleeding episode can be as high as 50%, leading many doctors to recommend surgical resection after a second bleeding episode, similar to recommendations made for recurrent diverticulitis [41, 63]. The diagnosis and treatment of lower gastrointestinal bleeds require a coordinated approach. After fluid resuscitation, angiography, nuclear bleeding scans and colonoscopy may be useful in patients with ongoing bleeding. Surgery may be required for patients whose medical management is unsuccessful.

References

- 1 Jun S, Stollman N: Epidemiology of diverticular disease. *Best Pract Res Clin Gastroenterol* 2002;16:529–542.
- 2 Mendeloff AI: Thoughts on the epidemiology of diverticular disease. *Clin Gastroenterol* 1986;15:855–877.
- 3 Kyle AO, Tinckler LF, De Beaux J: Incidence of diverticulitis. *Scand J Gastroenterol* 1967;2:77–80.
- 4 Hjern F, Johansson C, et al: Diverticular disease and migration – the influence of acculturation to a Western lifestyle on diverticular disease. *Aliment Pharmacol Ther* 2006;23:797–805.
- 5 Painter NS, Burkitt DP: Diverticular disease of the colon: a deficiency disease of Western civilization. *BMJ* 1971;ii:450–454.
- 6 Painter NS, Burkitt DP: Diverticular disease of the colon, a 20th century problem. *Clin Gastroenterol* 1975;4:3–21.
- 7 Parks TG: Natural history of diverticular disease of the colon. *Clin Gastroenterol* 1975;4:53–69.
- 8 Salzman H, Lillie D: Diverticular disease: diagnosis and treatment. *Am Fam Physician* 2005;72:1229–1234.
- 9 Reisman Y, Ziv Y, Kravrovitc D, et al: Diverticulitis: the effect of age and location on the course of disease. *Int J Colorectal Dis* 1999;14:250–254.
- 10 Tursi A: Acute diverticulitis of the colon – current medical therapeutic management. *Expert Opin Pharmacother* 2004;5:55–59.
- 11 Roberts PL, Veidenheimer MC: Current management of diverticulitis. *Adv Surg* 1994;27:189–208.
- 12 Reinus JF, Brandt LJ: Vascular ectasias and diverticulosis: common causes of lower intestinal bleeding. *Gastroenterol Clin North Am* 1994;23:1–20.
- 13 Slack W: The anatomy, pathology and some clinical features of diverticulitis of the colon. *Br J Surg* 1962;50:185–190.
- 14 Simpson J, Scholefield JH, Spiller RC: Pathogenesis of colonic diverticula. *Br J Surg* 2002;89:546–554.
- 15 Stollman N, Raskin JB: Diverticular disease of the colon. *Lancet* 2004;363:631–639.
- 16 Di Mario F, Comparato G, et al: Use of mesalazine in diverticular disease. *J Clin Gastroenterol* 2006;40:S155–S159.
- 17 Ghorai S, Ulbright TM, Douglas K, et al: Endoscopic findings of diverticular inflammation in colonoscopy patients with clinical acute diverticulitis: prevalence and endoscopic spectrum. *Am J Gastroenterol* 2003;98:76–84.
- 18 Makapugay LM, Dean PJ: Diverticular disease-associated chronic colitis. *Am J Surg Pathol* 1996;20:94–102.
- 19 Peppercorn MA: The overlap of inflammatory bowel disease and diverticular disease. *J Clin Gastroenterol* 2004;38(suppl 1):S8–S10.
- 20 Sheperd NA: Diverticular disease and chronic idiopathic inflammatory bowel disease: associations and masquerades. *Gut* 1996;38:801–802.
- 21 Tursi A: Mesalazine for diverticular disease of the colon – a new role for an old drug. *Expert Opin Pharmacother* 2005;6:69–74.
- 22 Boulos PB, Karamanolis DG, Salmon PR, Clark CG: Is colonoscopy necessary in diverticular disease? *Lancet* 1984;ii:95–96.
- 23 Wolff W, Shinya H: Colonoscopy. *N Engl J Med* 1973;288:974–975.
- 24 Williams CB, Lane RH, Sakai Y: Colonoscopy: an air-pressure hazard. *Lancet* 1973;ii:729.
- 25 Aldoori WH, Giovannucci EL, Rockett HR, Sampson L, Rimm EB, Willett WC: A prospective study of dietary fiber types and symptomatic diverticular disease in men. *J Nutr* 1998;128:714–719.
- 26 Fric P, Zavoral M: The effect of non-pathogenic *Escherichia coli* in symptomatic uncomplicated diverticular disease of the colon. *Eur J Gastroenterol Hepatol* 2003;15:313–315.
- 27 Papi C, Ciaco A, Koch M, et al: Efficacy of rifaximine in the treatment of symptomatic diverticular disease of the colon. A multicentre double-blind placebo-controlled trial. *Aliment Pharmacol Ther* 1995;9:33–39.
- 28 Latella G, Pimpo MT, Sottili S, et al: Rifaximin improves symptoms of acquired uncomplicated diverticular disease of the colon. *Int J Colorectal Dis* 2003;18:55–62.
- 29 Stollmann NH, Raskin JB: Diagnosis and management of diverticular disease of the colon. *Am J Gastroenterol* 1999;94:3110–3121.
- 30 Gore S, Sheperd NA, Wilkinson SP: Endoscopic crescentic fold disease of the sigmoid colon: the clinical and histopathological spectrum of a distinctive endoscopic appearance. *Int J Colorectal Dis* 1992;7:76–81.
- 31 Trespi E, Colla C, Panizza P, Polino MG, Venturini A, Bottani G, De Vecchi P, Matti C: Ruolo terapeutico e profilattico della mesalazina (5-ASA) nella malattia diverticolare sintomatica del crasso. *Minerva Gastroenterol Dietol* 1999;45:245–252.
- 32 Tursi A, Brandimarte G, Daffinà R: Long-term treatment with mesalazine and rifaximin vs. rifaximin alone for patients with recurrent attacks of acute diverticulitis of colon. *Dig Liver Dis* 2002;34:510–515.
- 33 Brandimarte G, Tursi A: Rifaximin plus mesalazine followed by mesalazine alone is highly effective in obtaining remission of symptomatic uncomplicated diverticular disease. *Med Sci Monit* 2004;10:P170–P173.
- 34 Di Mario F, Aragona G, Leandro G: Efficacy of mesalazine in the treatment of symptomatic diverticular disease. *Dig Dis Sci* 2005;50:581–586.
- 35 Doring E: Computerized tomography of colonic diverticulitis. *Crit Rev Diagn Imaging* 1992;33:421–435.
- 36 Hulnick DH, Megibow AJ, Balthazar EJ, Naidich DP, Bosniak MA: Computed tomography in the evaluation of diverticulitis. *Radiology* 1984;152:491–495.
- 37 Cho KC, Morehouse HT, Alterman DD, Thornhill BA: Sigmoid diverticulitis: diagnostic role of CT – comparison with barium enema studies. *Radiology* 1990;176:111–115.
- 38 Ambrosetti P, Jenny A, Becker C, Terrier TF, Morel P: Acute left colonic diverticulitis: compared performance of computed tomography and water-soluble contrast enema: prospective evaluation of 420 patients. *Dis Colon Rectum* 2000;43:1363–1367.
- 39 Standards Task Force of the American Society of Colon and Rectal Surgeons: Practice parameters for sigmoid diverticulitis: supporting documentation. *Dis Colon Rectum* 1995;38:126–132.
- 40 Parks TG: Natural history of diverticular disease of the colon: a review of 521 cases. *BMJ* 1969;iv:639–642.
- 41 Stollman NH, Raskin JB: Diagnosis and management of diverticular disease of the colon in adults: ad hoc practice parameters committee of the American College of Gastroenterology. *Am J Gastroenterol* 1999;94:3110–3121.
- 42 Kohler L, Sauerland S, Neugebauer E: Diagnosis and treatment of diverticular disease: results of a consensus development conference. *Surg Endosc* 1999;13:430–436.
- 43 Wong WD, Wexner SD, Lowry A, et al: Practice parameters for the treatment of sigmoid diverticulitis: supporting documentation. *Dis Colon Rectum* 2000;43:290–297.
- 44 Franklin ME Jr, Dorman JP, Jacobs M, Plasencia G: Is laparoscopic surgery applicable to complicated colonic diverticular disease? *Surg Endosc* 1997;11:1021–1025.
- 45 Smadja C, Sbai Idrissi M, Tahrat M, et al: Elective laparoscopic sigmoid colectomy for diverticulitis: results of a prospective study. *Surg Endosc* 1999;13:645–648.
- 46 Kockerling F, Schneider C, Reymond MA, et al: Laparoscopic resection of sigmoid diverticulitis: results of a multicenter study. *Surg Endosc* 1999;13:567–571.
- 47 Berthou JC, Charbonneau P: Elective laparoscopic management of sigmoid diverticulitis: results in a series of 110 patients. *Surg Endosc* 1999;13:457–460.
- 48 Stevenson A, Stitz R, Lumley J, Fielding G: Laparoscopically assisted anterior resection for diverticular disease: follow-up of 100 consecutive patients. *Ann Surg* 1998;227:335–342.
- 49 Lauro A, Alonso Poza A, Cirocchi R, et al: Laparoscopic surgery for colon diverticulitis. *Minerva Chir* 2002;57:1–5.

- 50 Oomen JLT, Engel AF, et al: Mortality after acute surgery for complications of diverticular disease of the sigmoid colon is almost exclusively due to patient-related factors. *Colorectal Dis* 2006;8:112–119.
- 51 Konvolinka CW: Acute diverticulitis under age forty. *Am J Surg* 1994;167:562–565.
- 52 Freischlag J, Bennion RS, Thompson JE Jr: Complications of diverticular disease of the colon in young people. *Dis Colon Rectum* 1986;29:639–643.
- 53 Chautems RC, Ambrosetti P, Ludwig A, Mermillod B, Morel P, Soravia C: Long-term follow-up after first acute episode of sigmoid diverticulitis: is surgery mandatory? A prospective study of 118 patients. *Dis Colon Rectum* 2002;45:962–966.
- 54 Reisman Y, Ziv Y, Kravrovitc D, Negri M, Wolloch Y, Halevy A: Diverticulitis: the effect of age and location on the course of disease. *Int J Colorectal Dis* 1999;14:250–254.
- 55 Spivak H, Weinrauch S, Harvey JC, Surick B, Ferstenberg H, Friedman I: Acute colonic diverticulitis in the young. *Dis Colon Rectum* 1997;40:570–574.
- 56 Goh H, Bourne R: Non-steroidal anti-inflammatory drugs and perforated diverticular disease: a case-control study. *Ann R Coll Surg Engl* 2002;84:93–96.
- 57 Mitchell KL, Shaheen NJ: Preventive therapy in perforated colonic diverticular disease? Calcium channel blockers may hold the key. *Gastroenterology* 2004;127:680–682.
- 58 Potter GD, Sellin JH: Lower gastrointestinal bleeding. *Gastroenterol Clin North Am* 1988;17:341–356.
- 59 Boley SJ, DiBiase A, Brandt LJ, Sammartano RJ: Lower intestinal bleeding in the elderly. *Am J Surg* 1979;137:57–64.
- 60 Gostout CJ, Wang KK, Ahlquist DA, et al: Acute gastrointestinal bleeding: experience of a specialized management team. *J Clin Gastroenterol* 1992;14:260–267.
- 61 Peura DA, Lanza FL, Gostout CJ, Foutch PG: The American College of Gastroenterology Bleeding Registry: preliminary findings. *Am J Gastroenterol* 1997;92:924–928.
- 62 Longstreth GF: Epidemiology and outcome of patients hospitalized with acute lower gastrointestinal hemorrhage: a population-based study. *Am J Gastroenterol* 1997;92:419–424.
- 63 McGuire HH Jr, Haynes BW Jr: Massive hemorrhage for diverticulosis of the colon: guidelines for therapy based on bleeding patterns observed in fifty cases. *Ann Surg* 1972;175:847–855.
- 64 Zuckerman GR, Prakash C: Acute lower intestinal bleeding. II. Etiology, therapy, and outcomes. *Gastrointest Endosc* 1999;49:228–238.
- 65 Meyers MA, Alonso DR, Gray GF, Baer JW: Pathogenesis of bleeding colonic diverticulosis. *Gastroenterology* 1976;71:577–583.
- 66 Casarella WJ, Kanter IE, Seaman WB: Right-sided colonic diverticula as a cause of acute rectal hemorrhage. *N Engl J Med* 1972;286:450–453.
- 67 McGuire HH Jr: Bleeding colonic diverticula: a reappraisal of natural history and management. *Ann Surg* 1994;220:653–656.
- 68 Wong SK, Ho YH, Leong AP, Seow-Choen F: Clinical behavior of complicated right-sided and left-sided diverticulosis. *Dis Colon Rectum* 1997;40:344–348.
- 69 Wilcox CM, Alexander LN, Cotsonis GA, Clark WS: Non-steroidal anti-inflammatory drugs are associated with both upper and lower gastrointestinal bleeding. *Dig Dis Sci* 1997;42:990–997.
- 70 Aldoori WH, Giovannucci EL, Rimm EB, Wing AL, Willett WC: Use of acetaminophen and non-steroidal anti-inflammatory drugs: a prospective study and the risk of symptomatic diverticular disease in men. *Arch Fam Med* 1998;7:255–260.