

# Isolated Subarachnoidal Hemorrhage following Carotid Endarterectomy

Marie Bodenant   Didier Leys   Christian Lucas

Department of Neurology, University of Lille, Roger Salengro Hospital, Lille, France

## Key Words

Subarachnoidal hemorrhage · Hyperperfusion syndrome · Headache · Carotid endarterectomy

## Abstract

Cerebral hyperperfusion syndrome is a rare but well-described complication following carotid endarterectomy or stenting. Clinical signs are ipsilateral, throbbing, unilateral headache with nausea or vomiting, seizures, and neurological deficits, with or without intracerebral abnormalities on CT scan, such as brain edema or intracerebral hemorrhage. Subarachnoidal hemorrhage is rarely described especially if it occurs isolated. We describe a 74-year-old man with a history of high blood pressure, hypercholesterolemia, atrioventricular block with pacemaker, and ischemic cardiopathy with coronary bypass. He underwent right carotid endarterectomy for a 90% NASCET asymptomatic stenosis. Four days after surgery, he complained of unusual headaches with right, throbbing hemicrania. Nine days after surgery, he presented with left hemiplegia and a partial motor seizure. He had fluctuant altered consciousness, left hemiplegia, and left visual and sensory neglect. Brain CT showed right frontal subarachnoidal hemorrhage without parenchymal bleeding. Cerebral angiography found no cerebral aneurysm, no vascular malformation, but a vasospasm of the left middle cerebral artery. Transcranial Doppler confirmed this vasospasm. Evolution was favorable with no recurrence of seizures but with an improvement of the neurological deficits and vasospasm. Physicians should bear in mind this very rare complication of endarterectomy and immediately perform neuroimaging in case of unusual headache following endarterectomy or angioplasty.

## Introduction

Cerebral hyperperfusion syndrome (CHS) is a rare (0–3%) but well-characterized complication after carotid endarterectomy (CEA). It can occur any time during the 28

days following surgery, but most studies report onset within several hours to seven days after surgery. It can also occur after carotid or vertebral angioplasty or stenting [1].

CHS is characterized by throbbing ipsilateral headache, neurological deficits such as confusion, visual or other focal disturbance, and seizures. Radiological aspects are brain edema, mass effect, focal infarct and petechial or massive ipsilateral hemorrhage [2].

Several mechanisms are involved in the pathophysiology of CHS. First, cerebral blood flow increases, a result of multiple factors such as removal of stenosis, release of vasoactive peptides, baroreceptor reflex breakdown or trigeminovascular reflex lesion during surgery. Hyperperfusion can exceed autoregulation capacity in a chronically hypoperfused hemisphere, cause transudation of fluid and vasogenic edema and increase vascular permeability by endothelial dysfunction. Bleeding may occur in the surrounding damaged brain tissue [2]. CHS is extremely rarely revealed by isolated subarachnoidal hemorrhage. We report a case with such a condition.

### Case Report

A 74-year-old man underwent endarterectomy for a right asymptomatic 90% NASCET stenosis of the internal carotid artery. He was a former smoker, with a history of high blood pressure, hypercholesterolemia, a pacemaker for an atrioventricular block and ischemic cardiopathy with a coronary bypass. His treatment included aspirin.

Four days after surgery, he developed unusual right, throbbing hemicrania. Nine days after surgery, he was referred to the emergency department for a left hemiplegia. Neurological examination showed altered and fluctuant consciousness, left hemiplegia and left visual and sensory neglect.

In the first hours, the patient presented with a partial motor secondary generalized seizure.

Emergency brain CT scan showed a right frontal subarachnoidal hemorrhage, without parenchymal bleeding (fig. 1). A middle cerebral artery (MCA) vasospasm was found on cerebral angiography, but no cerebral aneurysm or vascular malformation. Because of the pacemaker, brain MRI was not possible. Intracranial Doppler confirmed the MCA vasospasm.

Blood pressure was controlled by nicardipine. Treatment typically consists of levetiracetam (250 mg twice a day) to prevent seizure, nimodipine for vasospasm, and cessation of aspirin. Evolution was favorable and neurological status improved in 2 days, without recurrence of seizure or headache. Vasospasm was not found on control Doppler 24 h after the first one.

### Discussion

The incidence of CHS after CEA or carotid artery stenting (CAS) is about 3%. Intracranial hemorrhages occur in 0.37% of patients after CEA and in 0.74% after CAS [1]. Subarachnoidal hemorrhage can occur in association with intracerebral hemorrhage, but rarely occurs isolated.

To our knowledge, isolated subarachnoidal hemorrhages have been reported in 6 patients after CAS and in only 1 after CEA [3–8]. Another case is reported after CEA but in a patient with an ipsilateral aneurysm, and the cause of the bleeding was not identified [9]. The reason why subarachnoidal hemorrhage is more often associated with CAS than CEA is not known.

Our patient had some predisposing factors such as age, history of high blood pressure, severe carotid stenosis and treatment by aspirin. Many predisposing factors for CHS exist, especially preoperative severe cerebral blood flow decrease and pre- or postoperative

hyperperfusion. Identifying patients at risk of CHS is essential because supervision, screening and early treatment may improve outcome. Actually, various radiological techniques are studied to detect CHS precociously, such as signal intensity of the MCA on a time-of-flight sequence of a preoperative MRI [10], functional MRI [11] or Doppler [12].

The first symptom presented by our patient was headache. This may be an alerting symptom detectable in most patients useful in our aim to treat them early. Therefore, early recognition of cerebral hyperperfusion is important to minimize perioperative risks associated with CEA. The time of onset in the first week after CEA and the type of headache presented by our patient were typical. The combination of headache, seizures and focal deficit was also characteristic for the diagnosis of CHS.

Transcranial Doppler showed an MCA vasospasm maybe secondary to subarachnoidal hemorrhage, but no increase of the velocity of the MCA was found. In patients with CHS, transcranial Doppler typically shows a 150–300% increase in the ipsilateral MCA [13]. This increase can be explain by the controlateral spasm, Doppler performed two days after introducing treatment, or technical difficulties.

Because blood flow is pressure-dependent in patients with CHS, blood pressure control is recommended, but there are no data from randomized trials. Drugs of choice like clonidine or labetalol have to reduce arterial blood pressure but should have little effect on intracranial pressure [2]. Treatment of our patient with nicardipine can be discussed because it is a cerebral vasodilating agent, but in this case, the vasospasm was the indication for this treatment. Treatment of seizure is recommended, but there is no recommendation for prophylactic treatment [1].

Clinical outcome is dependent on the severity of CHS and on the timing of diagnosis and treatment. Neurological deficits seem to be reversible if there is no major damage caused by vasogenic edema or hemorrhage. Mortality and morbidity are significantly higher in patients with intracranial hemorrhage. Several studies reported that CHS, even if asymptomatic, is associated with impaired cognitive function [14].

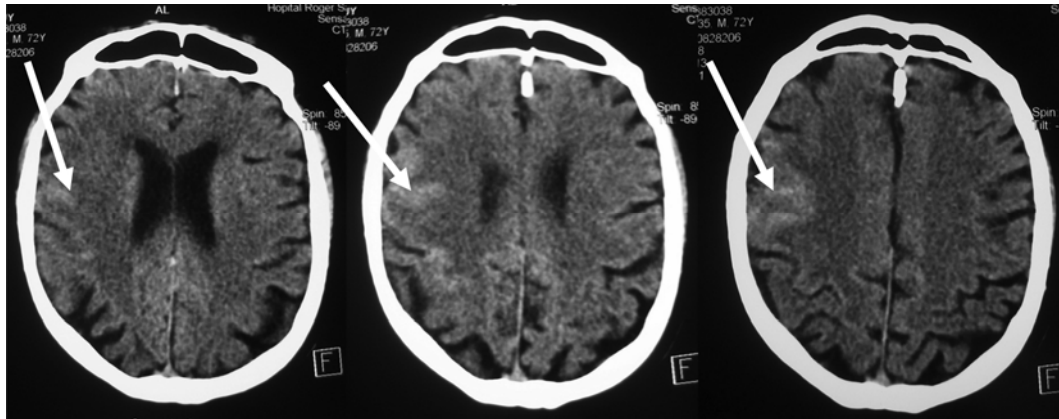
Hyperperfusion syndrome is a complication of CEA or CAS. It can be associated with intracerebral hemorrhage, but isolated subarachnoidal hemorrhage is extremely rare.

Early diagnosis of CHS is essential to improve prognosis. Headache after CEA or angioplasty must alert and requires immediate neuroimaging.

### Funding

Research group on Alzheimer's disease and stroke. Université Lille Nord de France, UDSL, Lille, France.

**Fig. 1.** Images of the emergency brain CT with an isolated right frontal subarachnoid hemorrhage (arrows).



## References

- 1 Moulakakis KG, Mylonas SN, Sfyroeras GS, Andrikopoulos V: Hyperperfusion syndrome after carotid revascularization. *J Vasc Surg* 2009;49:1060–1068.
- 2 van Mook WN, Rennenberg RJ, Schurink GW, van Oostenbrugge RJ, Mess WH, Hofman PA, de Leeuw PW: Cerebral hyperperfusion syndrome. *Lancet Neurol* 2005;4:877–888.
- 3 Ogasawara K, Sakai N, Kuroiwa T, Hosoda K, Iihara K, Toyoda K, Sakai C, Nagata I, Ogawa A; Japanese Society for Treatment at Neck in Cerebrovascular Disease Study Group: Intracranial hemorrhage associated with cerebral hyperperfusion syndrome following carotid endarterectomy and carotid artery stenting: retrospective review of 4,494 patients. *J Neurosurg* 2007;107:1130–1136.
- 4 Przewlocki T, Pieniazek P, Kablak-Ziembicka A, Motyl R, Moczulski Z, Tracz W: Subarachnoid hemorrhage after carotid artery stenting. *J Vasc Surg* 2007;45:1072–1075.
- 5 Terada T, Tsuura M, Matsumoto H, Masuo O, Tsumoto T, Yamaga H, Ohura Y, Itakura T: Hemorrhagic complications after endovascular therapy for atherosclerotic intracranial arterial stenoses. *Neurosurgery* 2006;59:310–318.
- 6 Hartmann M, Weber R, Zoubaa S, Schranz C, Knauth M: Fatal subarachnoid hemorrhage after carotid stenting. *J Neuroradiol* 2004;31:63–66.
- 7 Schoser BG, Heesen C, Eckert B, Thie A: Cerebral hyperperfusion injury after percutaneous transluminal angioplasty of extracranial arteries. *J Neurol* 1997;244:101–104.
- 8 Dalton ML: Subarachnoid hemorrhage after carotid endarterectomy. *J Vasc Surg* 1992;16:799.
- 9 Cheung RT, Eliasziw M, Meldrum HE, Fox AJ, Barnett HJ; North American Symptomatic Carotid Endarterectomy Trial Group: Risk, types, and severity of intracranial hemorrhage in patients with symptomatic carotid artery stenosis. *Stroke* 2003;34:1847–1851.
- 10 Kuroda H, Ogasawara K, Hirooka R, Kobayashi M, Fujiwara S, Chida K, Ishigaki D, Otawara Y, Ogawa A: Prediction of cerebral hyperperfusion after carotid endarterectomy using middle cerebral artery signal intensity in preoperative single-slab 3-dimensional time-of-flight magnetic resonance angiography. *Neurosurgery* 2009;64:1065–1071.
- 11 Chang TY, Liu HL, Lee TH, Kuan WC, Chang CH, Wu HC, Wu TC, Chang YJ: Change in cerebral perfusion after carotid angioplasty with stenting is related to cerebral vasoreactivity: a study using dynamic susceptibility-weighted contrast-enhanced MR imaging and functional MR imaging with a breath-holding paradigm. *AJNR Am J Neuroradiol* 2009;30:1330–1336.
- 12 Ogasawara K, Inoue T, Kobayashi M, Endo H, Yoshida K, Fukuda T, Terasaki K, Ogawa A: Cerebral hyperperfusion following carotid endarterectomy: diagnostic utility of intraoperative transcranial Doppler ultrasonography compared with single-photon emission computed tomography study. *AJNR Am J Neuroradiol* 2005;26:252–257.
- 13 Jørgensen LG, Schroeder TV: Defective cerebrovascular autoregulation after carotid endarterectomy. *Eur J Vasc Surg* 1993;7:370–379.
- 14 Ogasawara K, Yamadate K, Kobayashi M, Endo H, Fukuda T, Yoshida K, Terasaki K, Inoue T, Ogawa A: Postoperative cerebral hyperperfusion associated with impaired cognitive function in patients undergoing carotid endarterectomy. *J Neurosurg* 2005;102:38–44.