

Case Report

Long-Term Response after 94 Cycles of Trabectedin in a Patient with Metastatic Leiomyosarcoma of the Lower Extremity

Magda Cordeiro^a José Manuel Casanova^b Joana Rodrigues^b
João Freitas^b Ruben Fonseca^b Rui Caetano de Oliveira^c
Paulo Freitas Tavares^b

^aDepartment of Oncology, University Hospital Algarve, Faro Hospital, Faro, Portugal;

^bBone and Soft Tissue Tumor Unit, Coimbra University Hospital, Coimbra, Portugal;

^cDepartment of Pathology, Coimbra University Hospital, Coimbra, Portugal

Keywords

Trabectedin · Long-term response · Maintenance therapy

Abstract

Leiomyosarcomas of the lower extremity are extremely rare disorders and account for 10–15% of limb soft tissue sarcomas. These tumours have poor prognosis and even in early stages, patients persist at high risk for local and distant relapse; consequently, the treatment of advanced leiomyosarcoma of the lower extremity embodies a substantial defy. We present the case of a 73-year-old man diagnosed with metastatic lower extremity leiomyosarcoma of the hallux soft tissue, and with bone, lung and lymph node metastasis. After core needle biopsy confirmation of high-grade fusocellular sarcoma, the patient underwent surgery of the primary tumour and received anthracycline-based chemotherapy. However, after a 7-month progression-free survival period, a CT revealed lung disease progression. Sequentially, the patient was treated with trabectedin (Yondelis[®]) at a dose of 1.5 mg/m² resulting in complete remission of the lung metastasis and stable disease of the remaining lesions after 26 months of treatment. Afterwards, the patient started on maintenance therapy with trabectedin, resulting in long-lasting stable disease, as he was able to receive 94 cycles with very acceptable quality of life. Finally, in March 2019, the patient died of community-acquired pneumonia without objective progression disease. This clinical case reports the first patient ever treated with 94 cycles of trabectedin. Our results additionally confirm that trabectedin yields relevant oncostatic benefits with a manageable safety profile and without cumulative toxicities. Trabectedin properties enable a maintenance long-term therapy (until disease progression or unbearable toxicity), with a high impact on survival and with a preserved quality of life.

© 2020 The Author(s).
Published by S. Karger AG, Basel

Prof. Magda Cordeiro
Serviço de Oncologia, Centro Hospitalar Universitário do Algarve
Hospital de Faro, Rua Leão Penedo
PT-8000-386 Faro (Portugal)
mbcordeiro@ch Algarve.min-saude.pt

Introduction

Soft tissue sarcomas (STS) constitute a heterogeneous group of tumours that develop from mesenchymal cell precursors. Consequently, they differentiate in several cell lines (e.g., muscle, adipose, and connective tissue) and are associated with varying outcomes based on intrinsic diversity and heterogeneous responses to chemotherapy [1].

Soft tissue leiomyosarcomas are malignant tumours composed of cells showing distinct smooth muscle features and represent one of the most common types of STS, with an incidence of 11% [2, 3]. Overall survival (OS) of patients diagnosed with leiomyosarcomas ranges from 50% at 3 years to 64% at 5 years after diagnosis [4]. They usually present as a mass lesion and are capable of both local recurrence and distant metastasis; nevertheless, regional lymph node metastasis is rare [3]. The most relevant prognostic factors by far are tumour location and size, which are strongly interrelated. The most common locations of soft tissue leiomyosarcomas are the retroperitoneum and large blood vessels, most commonly the inferior vena cava [5]. Leiomyosarcomas involving non-retroperitoneal soft tissue sites are found most frequently in the lower extremity and account for 10–15% of all limb STS [6]. Among them, the intramuscular and subcutaneous localizations occur in approximately equal proportion, and some of these tumours show evidence of origin from a small to medium sized (unnamed) vein [7]. Leiomyosarcoma is commonly diagnosed among middle-aged or older persons, although it may develop in young adults and, even, in children. The gender incidence depends on tumour location, with predominantly women being diagnosed with retroperitoneal and inferior vena cava leiomyosarcomas, but with no differences in other soft tissue sites [3]. Non-retroperitoneal soft tissue leiomyosarcomas (also called somatic) are generally smaller than those in the retroperitoneum and more amenable to local control; thus, they have more favourable overall outcomes and better prognosis [3].

An “en-bloc” resection continues to be the cornerstone of management of early disease and the only curative option for leiomyosarcomas, whereas palliative systemic chemotherapy is the optimal treatment of advanced or unresectable disease. Standard first-line chemotherapy remains doxorubicin monotherapy with a median progression-free survival (PFS) of ~5 months and a median OS of ~12 months [1, 4]. The adjunct of high-dose ifosfamide failed to improve OS at the cost of increased toxicities in several trials, although a significant improvement of response rate (26 vs. 14%; $p < 0.0006$) and median PFS (7.4 vs. 4.6 months, $p = 0.003$) was observed with combined therapy and could represent relevant clinical benefit [8]. Other drugs or regimens frequently used in the therapeutic strategy of metastatic leiomyosarcomas include gemcitabine/docetaxel, gemcitabine/dacarbazine and pazopanib. Although not curative, they have demonstrated to slow down disease progression.

Trabectedin (Yondelis[®]) is a semisynthetic antineoplastic drug originally isolated from the sea squirt *Ecteinascidia turbinata* (ATC code: L01CX01). It is recommended as an effective second-line treatment for patients with advanced STS by European guidelines and undoubtedly represents an attractive option of treatment for leiomyosarcoma patients [1]. Trabectedin had recognized pleotropic mechanisms of action as, in addition to inducing direct growth arrest and death of malignant cells, it also has selective anti-inflammatory and immunomodulatory properties due to the inhibition of factors that promote tumour growth, angiogenesis, and metastasis [9]. The standard dose of trabectedin for the treatment of STS is 1.5 mg/m², administered as an intravenous infusion over 24 h every 3 weeks (dose reductions are allowed according to the tolerability in the patient). The most expected adverse events with trabectedin are nausea and vomiting, myelosuppression, fatigue, and transaminitis, all of which are usually transient and reversible. No alopecia or relevant cardiovascular toxicities are associated with trabectedin treatment. Likewise, no cumulative toxicities were described in clinical trials in patients treated with multiple cycles. Therefore, there were no pre-defined

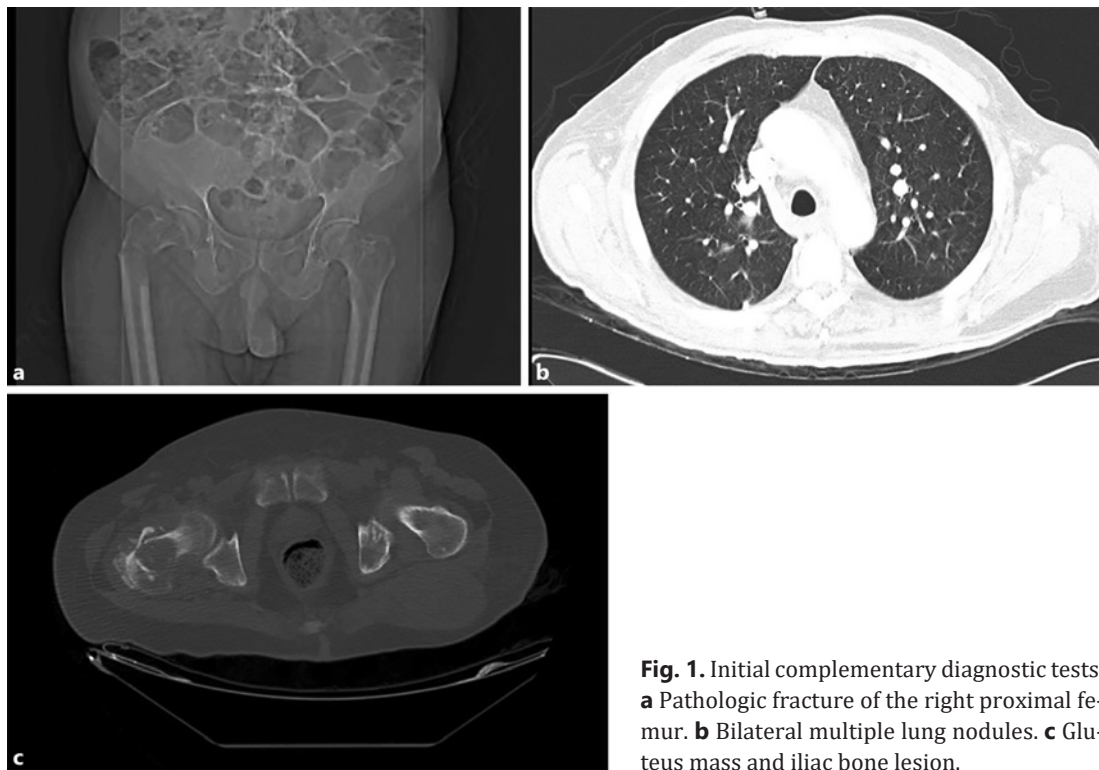


Fig. 1. Initial complementary diagnostic tests. **a** Pathologic fracture of the right proximal femur. **b** Bilateral multiple lung nodules. **c** Gluteus mass and iliac bone lesion.

limits to the number of cycles administered and clinical evidence supports treatment administration as long as clinical benefit is present [10].

Herein we report the case of a 73-year-old patient with metastatic leiomyosarcoma of the lower extremity that achieved a durable response after 94 cycles of trabectedin. During the patient's hospital course, consent for report of findings related to his treatment was obtained from family members.

Case Presentation

Our patient was a 73-year-old man, with a medical history of high blood pressure, diabetes, chronic obstructive pulmonary disease and hypercholesterolaemia. In January 2011, the patient was admitted to the orthopaedics ward with a fracture of the right proximal femur. In addition to a soft tissue mass of the right hallux, the physical exam highlighted pain and functional disability of the right hip. Pelvic-hip X-ray and a complete computed tomography (CT) scan revealed pathologic fracture of the right proximal femur, and bilateral lung nodules, gluteus mass, enlarged abdominal lymph node, bone lesions of the L2-L3 vertebra and ilium, suggestive of metastasis (Fig. 1). Following core needle biopsy and histologic confirmation of high-grade sarcoma, the case was angled as a metastatic STS of the right hallux and the patient was submitted to transmetatarsal amputation of the first right distal phalanx and large tumour resection osteotomy with prosthetic reconstruction of the right proximal femur. The histopathological study of all samples obtained during the surgical procedure revealed a spindle cell proliferation, with mild to moderate nuclear atypical and increased mitotic activity, with highly cellular areas (Fig. 2). Immunohistochemical ancillary studies revealed expression of vimentin, calponin, alpha-smooth muscle actin and muscle

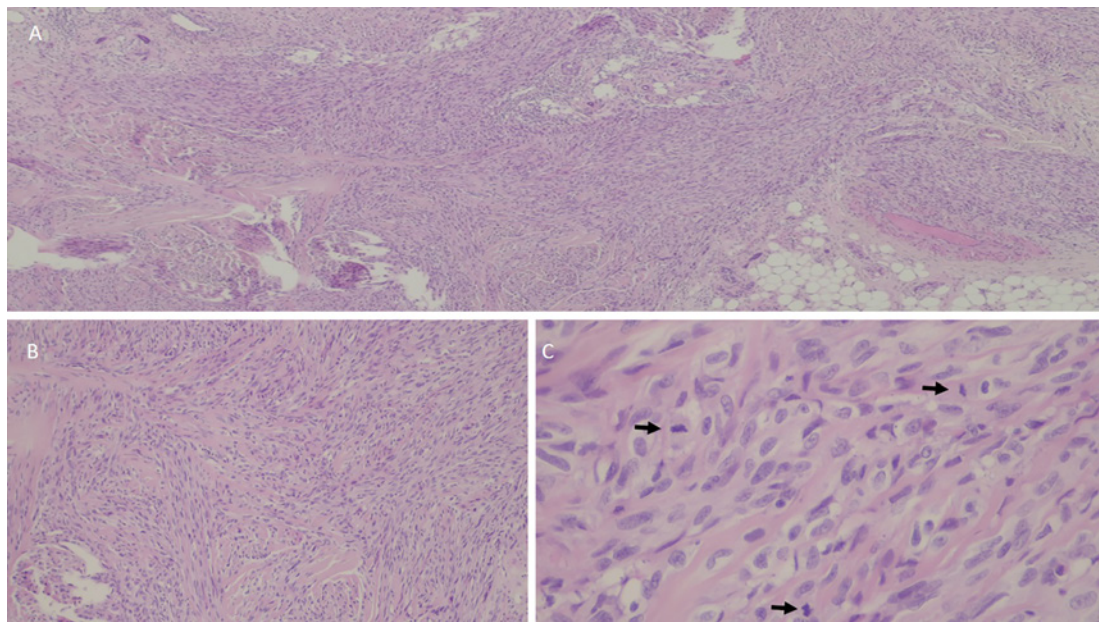


Fig. 2. Histologic examination of the surgical specimen. **A** Very cellular lesion, with fasciculated architecture and sometimes with a lobulated appearance. Haematoxylin-eosin (H&E) stain. $\times 40$. **B** Spindle cell proliferation in short and interwoven bundles of collagen. H&E stain. $\times 200$. **C** Mild to moderate cellular atypia with easily perceptible mitosis. H&E stain. $\times 400$.

actin monoclonal antibody, whereas S100 protein, epithelial membrane antigen, cytokeratin 34BE12 and CD34 were all negative; thus, giving us the final diagnosis of leiomyosarcoma.

In June 2011, a first-line chemotherapy with a combination of Adriamycin plus ifosfamide was initiated. A total of 4 cycles were administered with acceptable tolerance. Nevertheless, after a progression-free period of 7 months, a CT revealed abdominal lymph node disease progression. Sequentially, in February 2012 the patient started second-line treatment with trabectedin 1.5 mg/m^2 given as a 24-h infusion every 3 weeks. After a 26-month period of treatment, the patient achieved complete remission of cancer in the lung and muscle lesions, along with stable disease in the remaining lesions (Fig. 3). Afterwards, the patient continued on maintenance therapy with trabectedin at the same dosage, with disease stabilization as best response in all the succeeding exams, being able to receive up to 94 cycles. Trabectedin was well tolerated by the patient. He presented grade 1 fatigue, grade 2 neutropenia and reversible grade 2 transaminitis, as the most mentionable adverse reactions. Importantly, during the treatment, the patient had sustained good performance status (the Eastern Cooperative Oncology Group score = 1) and maintained an excellent quality of life, experiencing no late or cumulative toxicity, and being able to perform his usual activities. Finally, the patient died in March 2019 after being admitted with a community-acquired pneumonia, with no signs of objective progression disease.

Discussion

Leiomyosarcoma is an aggressive STS with scarce treatment options and short OS in the metastatic scenario. Usually, chemotherapy can only be administrated through a limited period since its efficacy decreases over time and because of cumulative toxicities, particularly cardiac and neuronal toxicities [1, 4].

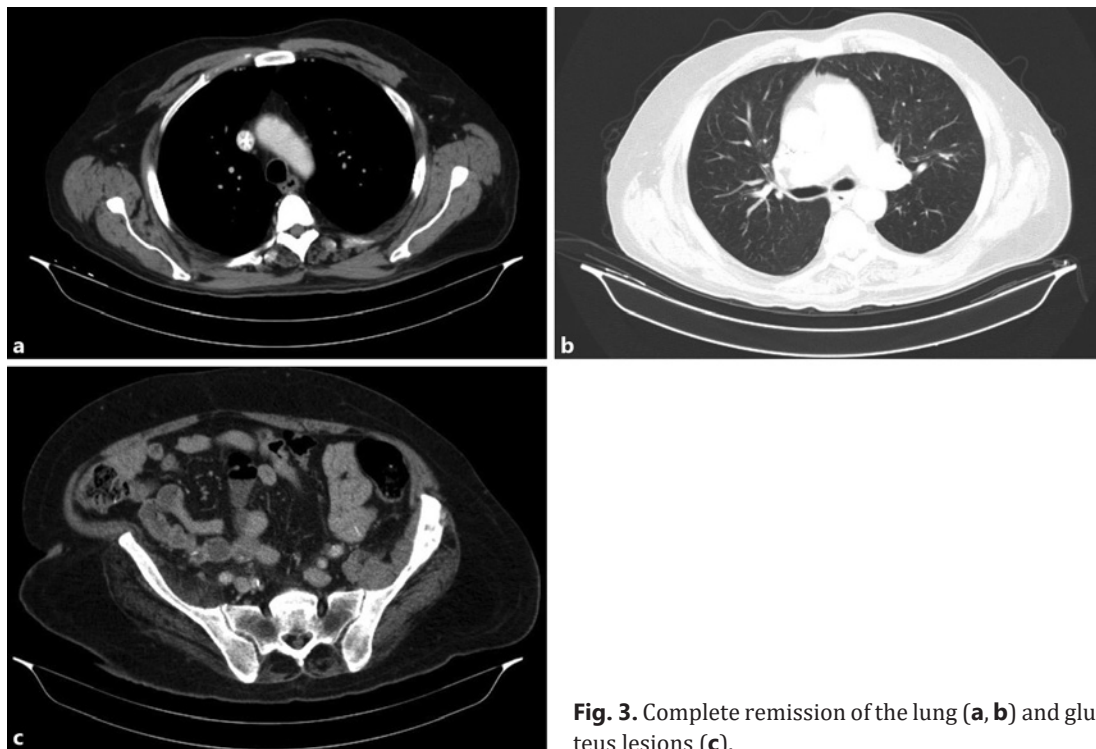


Fig. 3. Complete remission of the lung (a, b) and gluteus lesions (c).

The first pivotal study of trabectedin consisted in a randomized phase II comparison (ET-743-STS-201 trial) of two different treatment schedules of trabectedin administered either every 3 weeks (q3w) or weekly to anthracycline- and ifosfamide-pre-treated patients with metastatic leiomyosarcoma or liposarcoma [11]. The results showed that trabectedin 1.5 mg/m² given as a 24-h intravenous infusion in a q3w regimen obtained better disease control than weekly trabectedin 0.58 mg/m² (3-h infusion for 3 consecutive weeks in a 4-week cycle) in terms of longer time to progression (median TTP: 3.7 vs. 2.3 months; hazard ratio [HR]: 0.734, 95% confidence interval [CI]: 0.554–0.974; *p* = 0.0302) and PFS (median PFS: 3.3 vs. 2.3 months; HR: 0.755, 95% CI: 0.574–0.992; *p* = 0.0418). Based on these results, in 2007 trabectedin was the first marine-derived antineoplastic drug approved in 2007 in the European Union for the treatment of patients with advanced STS after failure of anthracyclines and ifosfamide, or for patients who are unsuited to receive these agents. Trabectedin efficacy and safety were further confirmed in trials performed in real-life clinical practice. In a retrospective study, 181 patients with metastatic STS were treated with trabectedin (1.5 mg/m² 24-h infusion, q3w) in 11 French centres [12]. The analyses included 57% of patients with leiomyosarcoma or liposarcoma (commonly abbreviated as L-sarcomas) and 43% with non-L-sarcoma subtypes and reached a median PFS of 3.6 months and a median OS of 16.1 months. Noteworthy, in this compassionate use study, trabectedin yielded similar or better PFS and OS values than those observed in clinical trials. In this and other trials, it has also been highlighted that patients receiving trabectedin in earlier lines showed a higher likelihood of achieving long-term benefit and longer PSF and OS than patients treated in third or later lines [13]. Another distinguished investigation is the one based on a retrospective study of the “RetrospectYon” database performed by the French Sarcoma Group in which 885 patients, diagnosed with all subtypes of STS and treated with trabectedin, were analysed [14]. This study demonstrates that the use of trabectedin in the daily clinical practice confirms the results obtained in the trials, as being an active agent in roughly all subtypes presenting a median PFS of >39%. Furthermore, the “RetrospectYon” analyses also underlined

that continuing with a maintenance treatment until progressive disease or unacceptable toxicity is correlated with an increase in PFS and OS as compared with treatment interruption after 6 months (median PFS: 11.7 vs. 7.6 months, $p = 0.003$; median OS: 24.9 vs. 7.6 months, $p = 0.001$). Those results were finally confirmed in the latter prospective randomized phase II T-DIS trial, achieving a median PFS of 7.2 versus 4 months in the continuation versus interruption group (HR: 1.97, 95% CI: 1.09–3.54; $p = 0.0200$), respectively, as well as a relevant impact on OS (2-year OS: 52.1% vs. 32.6%) [10]. More recently, a large randomized phase III trial compared trabectedin to the active drug dacarbazine for the treatment of patients with metastatic liposarcoma and leiomyosarcoma after failure of conventional chemotherapy [15]. The results of this trial also favoured trabectedin in terms of efficacy as trabectedin reached a 45% risk decrease of disease progression and death compared with dacarbazine (median PFS: 4.2 vs. 1.5 months; HR: 0.550, 95% CI: 0.44–0.70; $p < 0.0001$). In addition, trabectedin demonstrated a superior clinical benefit rate versus conventional dacarbazine of 34.2% for trabectedin and 18.5% for dacarbazine ($p = 0.001$) [32]. As a result, in 2015, trabectedin was also approved by the US Food and Drug Administration [15]. It is particularly important that in all trials trabectedin shows an acceptable safety profile, which allows prolonged periods of treatment with trabectedin with no accumulative toxicities.

In our case, the patient remained asymptomatic, with mild toxicity and very good performance status due to the trabectedin convenient safety profile. After 26 months of treatment, remission of lung lesions was achieved, as well as maintenance of disease control over time, with an extraordinary impact on survival. No progressive disease was observed; however, after 84 months of treatment, the patient died of a non-tumour-related cause.

In conclusion, this prolonged response, highlights the oncostatic rather than cytostatic effect of trabectedin. This is presumably related to its immunomodulating ability, underlying anti-inflammatory and antiangiogenic activity, which allows tumour microenvironment and cell growth control through long periods of time.

Acknowledgement

The authors would like to acknowledge Adnan Tanović for providing writing and editorial assistance for the manuscript.

Statement of Ethics

Informed consent was obtained from the patient's family for the presentation of the patient's case along with the associated medical imaging.

Disclosure Statement

The authors declare no potential conflicts of interest with respect to the research, authorship, and/or publication of this article.

Funding Sources

The authors received no financial support for the research and authorship of this article. Publication was supported by an unrestricted grant from PharmaMar, Spain.

Author Contributions

Magda Cordeiro, José Manuel Casanova, Joana Rodrigues and Paulo Freitas Tavares participated directly in the care of the patient, performed literature review, and assisted in drafting of the case report. All other authors performed literature review, and prepared, reviewed and approved the final version of the case report.

References

- 1 Casali PG, Abecassis N, Aro HT, Bauer S, Biagini R, Bielack S, et al. Soft tissue and visceral sarcomas: ESMO-EURACAN Clinical Practice Guidelines for diagnosis, treatment and follow-up. *Ann Oncol*. 2018 Oct 1;29(Suppl 4):iv268–iv69.
- 2 Ducimetiere F, Lurkin A, Ranchere-Vince D, Decouvelaere AV, Peoc'h M, Istier L, et al. Incidence of sarcoma histotypes and molecular subtypes in a prospective epidemiological study with central pathology review and molecular testing. *PLoS One*. 2011;6(8):e20294.
- 3 Fletcher CD. The evolving classification of soft tissue tumours – an update based on the new 2013 WHO classification. *Histopathology*. 2014 Jan;64(1):2–11.
- 4 Schoffski P, Cornillie J, Wozniak A, Li H, Hompes D. Soft tissue sarcoma: an update on systemic treatment options for patients with advanced disease. *Oncol Res Treat*. 2014;37(6):355–62.
- 5 Farshid G, Pradhan M, Goldblum J, Weiss SW. Leiomyosarcoma of somatic soft tissues: a tumor of vascular origin with multivariate analysis of outcome in 42 cases. *Am J Surg Pathol*. 2002 Jan;26(1):14–24.
- 6 Hashimoto H, Daimaru Y, Tsuneyoshi M, Enjoji M. Leiomyosarcoma of the external soft tissues. A clinicopathologic, immunohistochemical, and electron microscopic study. *Cancer*. 1986 May 15;57(10):2077–88.
- 7 Dahl I, Angervall L. Cutaneous and subcutaneous leiomyosarcoma. A clinicopathologic study of 47 patients. *Pathol Eur*. 1974;9(4):307–15.
- 8 Judson I, Verweij J, Gelderblom H, Hartmann JT, Schoffski P, Blay JY, et al. Doxorubicin alone versus intensified doxorubicin plus ifosfamide for first-line treatment of advanced or metastatic soft-tissue sarcoma: a randomised controlled phase 3 trial. *Lancet Oncol*. 2014 Apr;15(4):415–23.
- 9 D'Incalci M, Galmarini CM. A review of trabectedin (ET-743): a unique mechanism of action. *Mol Cancer Ther*. 2010 Aug;9(8):2157–63.
- 10 Le Cesne A, Blay JY, Domont J, Tresch-Bruneel E, Chevreau C, Bertucci F, et al. Interruption versus continuation of trabectedin in patients with soft-tissue sarcoma (T-DIS): a randomised phase 2 trial. *Lancet Oncol*. 2015 Mar;16(3):312–9.
- 11 Demetri GD, Chawla SP, von Mehren M, Ritch P, Baker LH, Blay JY, et al. Efficacy and safety of trabectedin in patients with advanced or metastatic liposarcoma or leiomyosarcoma after failure of prior anthracyclines and ifosfamide: results of a randomized phase II study of two different schedules. *J Clin Oncol*. 2009 Sep 1;27(25):4188–96.
- 12 Blay JY, Italiano A, Ray-Coquard I, Le Cesne A, Duffaud F, Rios M, et al. Long-term outcome and effect of maintenance therapy in patients with advanced sarcoma treated with trabectedin: an analysis of 181 patients of the French ATU compassionate use program. *BMC Cancer*. 2013 Feb 6;13:64.
- 13 Blay JY, Casali P, Nieto A, Tanovic A, Le Cesne A. Efficacy and safety of trabectedin as an early treatment for advanced or metastatic liposarcoma and leiomyosarcoma. *Future Oncol*. 2014 Jan;10(1):59–68.
- 14 Le Cesne A, Ray-Coquard I, Duffaud F, Chevreau C, Penel N, Bui Nguyen B, et al. Trabectedin in patients with advanced soft tissue sarcoma: a retrospective national analysis of the French Sarcoma Group. *Eur J Cancer*. 2015 Apr;51(6):742–50.
- 15 Demetri GD, von Mehren M, Jones RL, Hensley ML, Schuetz SM, Staddon A, et al. Efficacy and safety of trabectedin or dacarbazine for metastatic liposarcoma or leiomyosarcoma after failure of conventional chemotherapy: results of a phase III randomized multicenter clinical trial. *J Clin Oncol*. 2016 Mar 10;34(8):786–93.