

Does Barrett's Esophagus Regress after Surgery (or Proton Pump Inhibitors)?

Stuart Jon Spechler

Department of Medicine, VA North Texas Healthcare System, and the University of Texas Southwestern Medical Center at Dallas, Dallas, Tex., USA

Key Words

Barrett's esophagus · Gastroesophageal reflux disease · Antireflux surgery · Proton pump inhibitors

Abstract

Barrett's esophagus, the condition in which metaplastic columnar epithelium that predisposes to cancer development replaces the squamous epithelium that normally lines the distal esophagus, is a complication of gastroesophageal reflux disease (GERD). Metaplasia is a potentially reversible condition, and partial regression of Barrett's metaplasia has been documented with effective medical or surgical therapy for GERD. The important issue for patient management is not whether antireflux treatment causes Barrett's esophagus to regress, but rather whether antireflux therapy prevents cancer in Barrett's esophagus. Proton pump inhibitors (PPIs) would be expected to prevent this cancer because they heal reflux esophagitis, reduce exposure to a potential carcinogen (acid), and might prevent acid-induced proliferation and cancer-promoting cytokine secretion by esophageal epithelial cells. Furthermore, observational studies have shown that PPI use is associated with a decreased incidence of neoplasia in Barrett's esophagus. In theory, successful antireflux surgery, which eliminates the reflux of both acid and bile, should be better for cancer prevention than medical therapy,

which only decreases the reflux of acid. However, high-quality studies show no significant difference in cancer incidence between medically and surgically treated patients with GERD and Barrett's esophagus. Furthermore, for individual patients with nondysplastic Barrett's metaplasia, the cancer risk is so small and the number needed to treat for cancer prevention with surgery so large, that it does not matter whether or not surgery provides a tiny margin of extra protection against cancer beyond that provided by medical therapy. The cost and risks of the operation overwhelm any small, additional cancer protective benefit. Antireflux surgery is very effective at controlling the endoscopic signs and symptoms of GERD, but the operation should not be recommended to patients solely with the rationale that it protects against cancer better than medical therapy.

© 2014 S. Karger AG, Basel

Barrett's esophagus, a major risk factor for esophageal adenocarcinoma, is a metaplasia that develops as a consequence of gastroesophageal reflux disease (GERD) [1]. Metaplasia is the condition in which one adult cell type replaces another and, in a number of organs, it develops as a response to chronic inflammation. In the esophagus, GERD inflames the esophageal squamous epithelium and provides the abnormal intraluminal milieu that leads to

the healing of the reflux esophagitis through columnar metaplasia rather than through the regeneration of more squamous cells [2]. Metaplasia is a potentially reversible condition if the inciting inflammatory process can be treated effectively. After the effective treatment of GERD with fundoplication or proton pump inhibitors (PPIs), a number of studies (mostly observational) have documented partial and, infrequently, complete regression of Barrett's metaplasia in some patients [3–5]. In many of the reported cases of 'regression', it is difficult to exclude the possibility that Barrett's metaplasia did not regress, but instead was missed due to biopsy sampling error. It is especially difficult to exclude biopsy sampling error in cases of short-segment Barrett's esophagus, which is both patchy and limited in extent. Nevertheless, it seems highly likely that at least partial regression of Barrett's metaplasia occurs in some patients with effective medical or surgical antireflux therapy. What remains unclear is whether partial regression is clinically important.

Interest in regression of Barrett's esophagus with anti-reflux therapy has waned in recent years with the rising use of endoscopic ablative techniques like radiofrequency ablation, which can eradicate the metaplastic mucosa directly. Even before the availability of safe and effective ablative techniques, however, I would submit that the question of whether antireflux therapy causes partial regression of Barrett's metaplasia was never a key issue in patient management. The important issue has been whether antireflux therapy can prevent cancer in Barrett's esophagus. Partial regression of Barrett's metaplasia was considered a surrogate for decreased cancer risk, but it was never clear that mucosal regression was a valid surrogate. Rather than focus on the issue of metaplasia regression, which is of dubious importance, I will focus the remainder of this discussion on why antireflux therapy might be expected to prevent cancer in Barrett's esophagus.

Gastric Acid Suppression for Cancer Prevention

Table 1 lists four reasons why gastric acid suppression might be expected to prevent cancer in Barrett's esophagus.

Acid Reflux Causes Chronic Inflammation in the Esophagus

Acid reflux causes reflux esophagitis, a form of chronic inflammation, and chronic inflammation in a number of organs is well known to predispose to cancer develop-

Table 1. Reasons why gastric acid suppression might be expected to prevent cancer in Barrett's esophagus

Acid reflux causes chronic esophageal inflammation (reflux esophagitis) <i>Gastric acid suppression heals reflux esophagitis</i>
Acid causes DNA DSBs and therefore might be a carcinogen in Barrett's esophagus <i>Gastric acid suppression decreases carcinogen exposure</i>
Acid exposure promotes proliferation in Barrett's esophagus <i>Gastric acid suppression may prevent proliferation</i>
Acid stimulates esophageal secretion of cytokines that might contribute to carcinogenesis <i>Gastric acid suppression may prevent cytokine secretion</i> <i>PPIs can block cytokine secretion by esophageal epithelial cells through acid-independent mechanisms</i>

ment [6]. There is abundant evidence that acid suppression with PPIs heals reflux esophagitis [7] and, therefore, the elimination of that chronic esophageal inflammation with acid suppression might be expected to have cancer-preventing effects.

Acid Causes DNA Damage in Barrett's Epithelial Cells

There are in vitro and in vivo data to suggest that acid might be a carcinogen in Barrett's esophagus. Acid exposure causes nonneoplastic Barrett's epithelial (BAR-T) cells in vitro to produce reactive oxygen species, which are toxic molecules that can damage DNA [8]. DNA damage in the form of double-strand breaks (DSBs) can lead to genomic instability and promote cancer formation, and agents that induce DSBs can be considered carcinogens [8, 9]. Following acid exposure of BAR-T cells in vitro, immunofluorescence staining for phospho-H2AX reveals nuclear foci that indicate the presence of DSBs. The acid-induced formation of these DSBs can be prevented by pretreating the cells with either N-acetyl-L-cysteine (a reactive oxygen species scavenger) or disodium 4,4'-diisothiocyanatostilbene-2,2'-disulfonate, which prevents intracellular acidification by inhibiting the Cl⁻/HCO₃⁻ exchanger. These observations indicate that acid enters Barrett's epithelial cells and causes severe DNA damage through the generation of reactive oxygen species.

The in vitro observation that acid exposure causes DNA damage in Barrett's metaplastic cells was confirmed in a translational study in which endoscopic biopsy specimens of Barrett's metaplasia were taken from 6 patients

before and after the esophagus was perfused for 5 min with 0.1 M hydrochloric acid [8]. Western blots demonstrated that even this brief esophageal acid exposure increased phospho-H2AX expression in the Barrett's metaplasia of all 6 patients. These findings suggest that acid might be a carcinogen in Barrett's esophagus and, therefore, gastric acid suppression might protect against cancer by decreasing esophageal exposure to this carcinogen.

Acid Exposure Promotes Proliferation in Barrett's Esophagus

Biopsy specimens of Barrett's metaplasia maintained in organ culture and exposed to a pulse of acid show evidence of increased proliferation and increased expression of cyclooxygenase-2 [10, 11]. Acid exposure also causes Barrett's-associated adenocarcinoma cell lines to activate the mitogen-activated protein kinase and protein kinase C pathways, and to increase proliferation [10, 12]. In patients with Barrett's esophagus, esophageal acid perfusion for only 3 min causes activation of the mitogen-activated protein kinase pathways in Barrett's metaplasia [12]. In a study in which patients had biopsies taken from their Barrett's esophagus at baseline and after 6 months of treatment with PPIs, the expression of PCNA (a proliferation marker) decreased significantly in biopsy specimens from 24 patients in whom PPIs had normalized esophageal acid exposure, but not in biopsies from the 15 with persistently abnormal acid reflux [13]. Another study found no significant change in the proliferative activity of Barrett's metaplasia in 22 patients treated with PPIs for 2 years, whereas proliferative activity increased significantly in 23 patients treated for the same time with histamine H₂-receptor antagonists, which are far less effective at reducing gastric acid secretion [14]. In the latter two clinical studies, it is not possible to determine whether acid suppression decreased proliferation directly, i.e. by eliminating a direct proproliferative effect of acid on the epithelial cells, or indirectly through the anti-inflammatory effects of healing reflux esophagitis. Irrespective of the mechanism, however, it appears that acid suppression with PPIs decreases proliferation in Barrett's metaplasia and, therefore, might protect against cancer development.

In contrast to the above-mentioned studies suggesting that acid has proproliferative effects in Barrett's esophagus, one study using nonneoplastic Barrett's epithelial cells suggested that acid might have antiproliferative effects [15]. In this study, BAR-T cells exposed to acid exhibited a decrease in cell number at 24 h. Initially, these findings suggested the possibility that acid might have

beneficial effects on proliferation in nondysplastic Barrett's esophagus. Subsequently, the same investigators found that this antiproliferative effect was the result of acid-induced DNA damage causing cell cycle arrest [8]. Although the aforementioned study did show that acid exposure has a temporary antiproliferative effect in benign Barrett's epithelial cells [15], this observation should not be construed as a beneficial effect. The cells merely stopped proliferating temporarily while they attempted to repair the DNA damage caused by the acid exposure.

Acid Stimulates Esophageal Secretion of Cytokines

Nonneoplastic human esophageal squamous cells exposed to acid and bile salts dramatically increase their production of IL-8, a chemokine that is a major mediator of inflammation and that has proproliferative effects [16]. In a rat model of reflux esophagitis produced by esophago-duodenostomy, immunohistochemical staining shows robust expression of IL-8 in the epithelial cells of the reflux-inflamed esophagus [16]. Thus, acid reflux appears to stimulate the production of a proinflammatory, proproliferative chemokine (IL-8) that conceivably could contribute to esophageal carcinogenesis. Gastric acid suppression with PPIs might prevent this reflux-stimulated production of IL-8.

A recent report has shown that the PPIs also might block esophageal chemokine production through mechanisms that are independent of their antisecretory effects [17]. In this study, the investigators exposed human esophageal squamous cells to an acidic bile salt medium, which caused the cells to express IL-8 mRNA and protein by activating the IL-8 promoter through NF- κ B and activator protein (AP)-1 binding. Omeprazole inhibited that acidic bile salt-stimulated IL-8 expression by blocking the nuclear translocation of p65 (an NF- κ B subunit) and by blocking the binding of p65, c-Jun and c-Fos (AP-1 subunits) to the IL-8 promoter. These findings indicate that omeprazole inhibits IL-8 expression through effects on NF- κ B and AP-1 that are entirely independent of PPI effects on gastric acid secretion. Conceivably, these acid-independent anti-inflammatory effects also could help to prevent esophageal cancer.

PPIs and Reflux

Omeprazole was the first PPI introduced into clinical practice in the USA in 1989. Figure 1 shows that the rising incidence of esophageal adenocarcinoma clearly preceded the introduction of PPIs [18]. Although figure 1 sug-

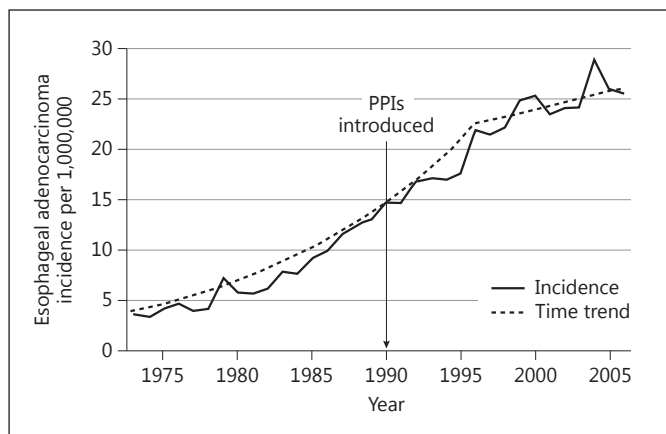


Fig. 1. Overall incidence trend for esophageal adenocarcinoma in the USA (1973–2006; adapted from reference [18]).

gests that the time trend of the rise in this cancer might be leveling off somewhat, the figure also shows that the incidence of esophageal adenocarcinoma has not declined dramatically since the introduction of PPIs. Since PPIs are very effective at controlling gastric acid, this suggests that perhaps the reflux of something other than acid might be contributing to carcinogenesis in Barrett's esophagus. One of the prime suspects for that other potentially carcinogenic material is bile acid.

In a recent translational study, the investigators took biopsies of Barrett's metaplasia from 3 patients before and after perfusing the esophagus for 5 min with a physiologic solution of the bile acid DCA (deoxycholic acid) [19]. Western blots revealed increased expression of phospho-H2AX, a marker of DNA damage, after DCA perfusion in biopsy specimens from all 3 patients. Severe and irreparable DNA damage usually triggers apoptosis (programmed cell death) that destroys cells with potentially carcinogenic genetic alterations. In addition to causing DNA damage, however, the investigators found that DCA also activated NF- κ B proteins, which can prevent apoptosis. This study shows that, in Barrett's metaplasia, bile acids cause DNA damage while simultaneously activating NF- κ B, which can prevent the apoptosis that should be induced by DNA damage. This might enable the survival of Barrett's cells that have sustained potentially carcinogenic genetic alterations. Unfortunately, PPIs do not prevent bile reflux.

PPIs do not entirely eliminate acid reflux in Barrett's esophagus either, and a number of studies have documented that patients with Barrett's esophagus often con-

tinue to have pathological levels of acid reflux despite PPI therapy. In one study of 31 patients with long-segment Barrett's esophagus treated with esomeprazole 40 mg twice a day, pH monitoring revealed that the gastric pH remained above 4 for 81% of the day, a level of gastric acid suppression similar to that found in studies of healthy volunteers on a similar PPI dosage [20]. This showed that Barrett's esophagus patients had no unusual resistance to the acid-suppressing effects of PPIs. However, simultaneous esophageal pH monitoring showed that 7 of the 31 patients (23%) had abnormal acid reflux despite the good gastric acid suppression. This suggests that the so-called 'PPI resistance' of Barrett's esophagus patients is due to their strong propensity for reflux. In other words, the antireflux mechanism in patients with long-segment Barrett's esophagus is so poor that, even during PPI treatment, the small amount of acid that remains in the stomach still refluxes into the esophagus.

PPI Side Effects

The PPIs have four broad categories of potential side effects [21]. It has been proposed that PPIs might: (1) increase the risk of upper gastrointestinal tract cancer development, (2) increase susceptibility to a variety of infections, (3) affect the absorption or metabolism of certain vitamins and minerals, and (4) cause miscellaneous problems.

Gastric acid secretion is stimulated by the hormone gastrin, which is made in the gastric antrum. In a classic, feedback loop arrangement, gastrin stimulates acid production in the gastric fundus, and acid inhibits antral gastrin production. When PPIs block acid secretion, antral gastrin production continues unabated and serum gastrin levels rise [22]. Without acid, furthermore, bacteria can colonize the stomach [23]. Gastrin is a growth factor that has been shown to increase proliferation in Barrett's metaplasia [24]. In addition, bacteria can deconjugate bile acids, which can injure the esophagus at neutral pH levels, and bacteria can convert dietary nitrates into potentially carcinogenic N-nitroso compounds [25]. In addition, some studies suggest that PPIs might promote gastric atrophy in patients who are infected with *Helicobacter pylori* [26]. All this could increase the risk for developing cancers of the upper gastrointestinal tract.

Gastric acid plays an important role in killing ingested bacteria, and some reports allege that acid suppression with PPIs might increase the risk of enteric infections [27], pneumonias [28], *Clostridium difficile* colitis [29], small intestinal bacterial overgrowth [30], and spontaneous

bacterial peritonitis in patients with cirrhosis [31]. PPIs have been shown to interfere with the absorption of vitamin B₁₂ and to cause hypomagnesemia, and PPI effects on magnesium and calcium metabolism might increase the risk for bone fractures [32, 33]. Finally, there are reports of miscellaneous problems associated with PPI use, including interstitial nephritis [34], microscopic colitis [35], food allergy development [36], decreased efficacy of clopidogrel [37], and increased frequency of cardiovascular events in patients with acute coronary syndromes [38].

Most of the problems described above are more theoretical than real, and the PPIs have an outstanding track record of safety over the past 25 years. However, GERD and Barrett's esophagus are lifelong diseases, and these potential problems should be considered when prescribing chronic PPI therapy.

PPIs and Cancer Risk in Barrett's Esophagus

Despite the reasons to suspect that PPIs could increase the risk for upper gastrointestinal tract malignancy discussed above, there are no credible events that substantiate this concern. Furthermore, a number of observational studies suggest that PPIs protect against cancer development in patients with Barrett's esophagus. In a long-term follow-up study of 236 veteran patients with Barrett's esophagus, the cumulative incidence of dysplasia at 10 years was 21% for the patients who received PPI therapy compared to 58% for the patients who did not [39]. In an update of this study that included 344 veteran patients, patients who were given a prescription for PPIs had a significant reduction in the risk of developing high-grade dysplasia and cancer, with a hazard ratio of 0.43 (95% CI: 0.21–0.83) [40]. In an Australian study of 350 Barrett's patients followed for a median of 4.7 years, patients who delayed using PPIs for ≥ 2 years after the diagnosis of Barrett's esophagus had a significantly increased risk for developing low-grade dysplasia (hazard ratio 5.6, 95% CI: 2.0–15.7) and for developing high-grade dysplasia or cancer (hazard ratio 20.9, 95% CI: 2.8–158) [41]. Finally, a study of 540 Dutch patients with Barrett's esophagus followed for a median of 5.2 years found that PPI use was associated with a 75% reduction in the risk of neoplastic progression [42].

In summary, there is a plausible rationale for using PPIs in chemoprevention for patients with Barrett's esophagus. PPIs heal reflux esophagitis, reduce exposure to a potential carcinogen (acid), and might prevent acid-induced proliferation and cancer-promoting cytokine se-

cretion by esophageal epithelial cells. A number of observational studies have shown that PPI use protects against neoplasia in Barrett's esophagus, and the theoretical cancer-promoting effects of PPIs have not been substantiated in any observational study. Consequently, it seems prudent to control esophageal acid exposure in patients with Barrett's esophagus, which can be done either with PPIs or with antireflux surgery.

Antireflux Surgery and Cancer Risk

One can make excellent theoretical arguments about why surgery should be better than medical therapy for cancer prevention in Barrett's esophagus [43]. As discussed, medical therapy for GERD with PPIs targets acid exclusively, but acid clearly is not the only potentially harmful agent in refluxed gastric juice. An effective antireflux operation stops the reflux of all noxious material, including the potentially carcinogenic bile acids, and a successful operation obviates the potential side effects of PPIs. Furthermore, a number of reports of uncontrolled observational studies have suggested that surgically treated patients with Barrett's esophagus develop less dysplasia and less cancer than medically treated patients [44, 45]. Unfortunately, antireflux surgery can also have serious complications including dysphagia, gas-bloat syndrome, diarrhea, and (rarely) death [46]. In addition, high-quality studies, which include two prospective randomized trials [47, 48], two meta-analyses [49, 50], and three cohort studies using very large databases [51–53], have found no significant differences in cancer incidence between medically and surgically treated GERD patients with Barrett's esophagus.

Low Cancer Incidence in Nondysplastic Barrett's Esophagus and Implications for Patient Management

In the USA, the national incidence of esophageal adenocarcinoma has risen from 3.6 per million in 1973 to 25.6 per million in 2006 [18]. That is a more than sevenfold increase over the course of only three decades. Ironically, however, although the incidence of this cancer has been rising, estimates of cancer risk for individual patients with nondysplastic Barrett's esophagus have been getting lower. In the 1990s, this risk was estimated at 1% per year [54]. In 2000, Shaheen et al. [55] argued convincingly that this old estimate was exaggerated because it was based on reports

that suffered from publication bias, and estimated the annual risk at 0.5% per year. Several reports of large studies published within the past 2 years have described an even lower risk. For example, a meta-analysis of 57 reports including more than 11,000 patients followed for more than 58,000 patient-years found a cancer incidence of only 0.33% per year [56]. A multicenter US study with more than 6,000 patient-years of follow-up found an annual cancer incidence of only 0.27% [57]. A large population-based study from Northern Ireland also found an annual cancer incidence of 0.27% [58]. Moreover, the largest population-based study to date followed Danish patients who had Barrett's with nondysplastic intestinal metaplasia for more than 56,000 person-years, and found the overall cancer incidence to be only 0.12% [59]. These recent reports suggest that the cancer risk for patients with nondysplastic Barrett's esophagus is only approximately 0.25% per year, a risk lower than had been thought for many years.

The low risk of cancer for individual patients with nondysplastic Barrett's esophagus has important implications for patient management, especially if one considers the number needed to treat (NNT) for cancer prevention. The formula for determining the NNT is 1 divided by the absolute risk reduction. For example, if treatment X results in an absolute reduction in the risk of a bad outcome by 20%, then the NNT is 1 divided by 20%, which equals 5. In this situation, one only needs to treat 5 patients with treatment X to prevent one bad outcome.

Now, consider the following question. If antireflux surgery prevents cancer in Barrett's esophagus, then how many patients would that therapy need to prevent 1 cancer case in 1 year? Data discussed above suggest that the annual risk for cancer in Barrett's esophagus is 0.25%. If we assume that antireflux surgery is highly effective and that it decreases the risk of cancer development by one half (note: there is no proof that any GERD therapy decreases the cancer risk at all, but for this discussion assume that

antireflux surgery is a highly effective anticancer therapy), then antireflux surgery decreases the cancer risk from 0.25 to 0.125%, which is an absolute risk reduction of 0.125%. Therefore, the NNT is 1 divided by 0.125%, which equals 800. This means that one would need to treat 800 patients with antireflux surgery to prevent 1 cancer case in 1 year. Such a large NNT can only be justified for a very inexpensive procedure that has virtually no side effects. Clearly, antireflux surgery does not meet those criteria.

In conclusion, there is abundant indirect evidence to suggest that effective antireflux therapy, medical or surgical, protects against cancer in Barrett's esophagus. In theory, successful antireflux surgery, which eliminates the reflux of both acid and bile, should be better for cancer prevention than medical therapy, which only decreases the reflux of acid. But high-quality studies show no significant difference in cancer incidence between medically and surgically treated patients with GERD and Barrett's esophagus. Furthermore, for individual patients with nondysplastic Barrett's, the cancer risk is so small and the NNT to prevent cancer with surgery is so large, that it does not matter whether or not surgery provides a tiny margin of extra protection against cancer beyond that provided by medical therapy. The cost and risks of the operation totally overwhelm any small, additional cancer protective benefit. Antireflux surgery is very effective at controlling the endoscopic signs and symptoms of GERD, and there are a number of good reasons to recommend this operation. However, antireflux surgery should not be recommended to patients solely with the rationale that it protects against cancer better than medical therapy.

Disclosure Statement

The author has been a consultant for Takeda Pharmaceuticals, Inc. and for Torax Medical, Inc.

References

- 1 Spechler SJ: Barrett esophagus and risk of esophageal cancer: a clinical review. *JAMA* 2013;310:627–636.
- 2 Burke ZD, Tosh D: Barrett's metaplasia as a paradigm for understanding the development of cancer. *Curr Opin Genet Dev* 2012;22:494–499.
- 3 Gurski RR, Peters JH, Hagen JA, DeMeester SR, Bremner CG, Chandrasoma PT, DeMeester TR: Barrett's esophagus can and does regress after antireflux surgery: a study of prevalence and predictive features. *J Am Coll Surg* 2003;196:706–713.
- 4 Peters FT, Ganesh S, Kuipers EJ, Sluiter WJ, Klinkenberg-Knol EC, Lamers CB, Kleibeuker JH: Endoscopic regression of Barrett's oesophagus during omeprazole treatment; a randomised double blind study. *Gut* 1999;45:489–494.
- 5 Haag S, Nandurkar S, Talley NJ: Regression of Barrett's esophagus: the role of acid suppression, surgery, and ablative methods. *Gastrointest Endosc* 1999;50:229–240.

- 6 Macarthur M, Hold GL, El-Omar EM: Inflammation and Cancer II. Role of chronic inflammation and cytokine gene polymorphisms in the pathogenesis of gastrointestinal malignancy. *Am J Physiol Gastrointest Liver Physiol* 2004;286:G515–G520.
- 7 Katz PO, Gerson LB, Vela MF: Guidelines for the diagnosis and management of gastroesophageal reflux disease. *Am J Gastroenterol* 2013;108:308–328.
- 8 Zhang HY, Hormi-Carver K, Zhang X, Spechler SJ, Souza RF: In benign Barrett's epithelial cells, acid exposure generates reactive oxygen species that cause DNA double-strand breaks. *Cancer Res* 2009;69:9083–9089.
- 9 Mills KD, Ferguson DO, Alt FW: The role of DNA breaks in genomic instability and tumorigenesis. *Immunol Rev* 2003;194:77–95.
- 10 Fitzgerald RC, Omary MB, Triadafilopoulos G: Dynamic effects of acid on Barrett's esophagus. An ex vivo proliferation and differentiation model. *J Clin Invest* 1996;98:2120–2128.
- 11 Shirvani VN, Ouatu-Lascar R, Kaur BS, Omary B, Triadafilopoulos G: Cyclooxygenase 2 expression in Barrett's esophagus and adenocarcinoma: ex vivo induction by bile salts and acid exposure. *Gastroenterology* 2000;118:487–496.
- 12 Souza RF, Shewmake K, Terada LS, Spechler SJ: Acid exposure activates the mitogen activated protein kinase pathways in Barrett's esophagus. *Gastroenterology* 2002;122:299–307.
- 13 Ouatu-Lascar R, Fitzgerald RC, Triadafilopoulos G: Differentiation and proliferation in Barrett's esophagus and the effects of acid suppression. *Gastroenterology* 1999;117:327–335.
- 14 Peters FT, Ganesh S, Kuipers EJ, Sluiter WJ, Karrenbeld A, de Jager-Krikken A, Klinkenberg-Knol EC, Lamers CB, Kleibeuker JH: Effect of elimination of acid reflux on epithelial cell proliferative activity of Barrett esophagus. *Scand J Gastroenterol* 2000;35:1238–1244.
- 15 Feagins LA, Zhang HY, Hormi-Carver K, Quinones MH, Thomas D, Zhang X, Terada LS, Spechler SJ, Ramirez RD, Souza RF: Acid has antiproliferative effects in nonneoplastic Barrett's epithelial cells. *Am J Gastroenterol* 2007;102:10–20.
- 16 Souza RF, Huo X, Mittal V, Schuler CM, Carmack SW, Zhang HY, Zhang X, Yu C, Hormi-Carver K, Genta RM, Spechler SJ: Gastroesophageal reflux may cause esophagitis through a cytokine-mediated mechanism, not by caustic (acid) injury. *Gastroenterology* 2009;137:1776–1784.
- 17 Huo X, Zhang X, Yu C, Zhang Q, Cheng E, Wang DH, Pham TH, Spechler SJ, Souza RF: In oesophageal squamous cells exposed to acidic bile salt medium, omeprazole inhibits IL-8 expression through effects on nuclear factor- κ B and activator protein-1. *Gut*, DOI: 10.1136/gutjnl-2013-305533.
- 18 Pohl H, Sirovich B, Welch HG: Esophageal adenocarcinoma incidence: are we reaching the peak? *Cancer Epidemiol Biomarkers Prev* 2010;19:1468–1470.
- 19 Huo X, Juergens S, Zhang X, Rezaei D, Yu C, Strauch ED, Wang JY, Cheng E, Meyer F, Wang DH, Zhang Q, Spechler SJ, Souza RF: Deoxycholic acid causes DNA damage while inducing apoptotic resistance through NF- κ B activation in benign Barrett's epithelial cells. *Am J Physiol Gastrointest Liver Physiol* 2011;301:G278–G286.
- 20 Spechler SJ, Sharma P, Traxler B, Levine D, Falk GW: Gastric and esophageal pH in patients with Barrett's esophagus treated with three esomeprazole dosages: a randomized, double-blind, crossover trial. *Am J Gastroenterol* 2006;101:1964–1971.
- 21 Spechler SJ: Barrett esophagus and risk of esophageal cancer: a clinical review. *JAMA* 2013;310:627–636.
- 22 Lamberts R, Creutzfeldt W, Struber HG, Brunner G, Solcia E: Long-term omeprazole therapy in peptic ulcer disease: gastrin, endocrine cell growth, and gastritis. *Gastroenterology* 1993;104:1356–1370.
- 23 Theisen J, Nehra D, Citron D, Johansson J, Hagen JA, Crookes PF, DeMeester SR, Bremner CG, DeMeester TR, Peters JH: Suppression of gastric acid secretion in patients with gastroesophageal reflux disease results in gastric bacterial overgrowth and deconjugation of bile acids. *J Gastrointest Surg* 2000;4:50–54.
- 24 Haigh CR, Attwood SE, Thompson DG, Jankowski JA, Kirtan CM, Pritchard DM, Varro A, Dimaline R: Gastrin induces proliferation in Barrett's metaplasia through activation of the CCK2 receptor. *Gastroenterology* 2003;124:615–625.
- 25 Williams C, McColl KE: Review article: proton pump inhibitors and bacterial overgrowth. *Aliment Pharmacol Ther* 2006;23:3–10.
- 26 Kuipers EJ: Proton pump inhibitors and *Helicobacter pylori* gastritis: friends or foes? *Basic Clin Pharmacol Toxicol* 2006;99:187–194.
- 27 Bavishi C, Dupont HL: Systematic review: the use of proton pump inhibitors and increased susceptibility to enteric infection. *Aliment Pharmacol Ther* 2011;34:1269–1281.
- 28 de Jager CP, Wever PC, Gemen EF, van Oijen MG, van Gageldonk-Lafeber AB, Siersema PD, Kusters GC, Laheij RJ: Proton pump inhibitor therapy predisposes to community-acquired *Streptococcus pneumoniae* pneumonia. *Aliment Pharmacol Ther* 2012;36:941–949.
- 29 Janarthanan S, Ditah I, Adler DG, Ehrnpreis MN: *Clostridium difficile*-associated diarrhea and proton pump inhibitor therapy: a meta-analysis. *Am J Gastroenterol* 2012;107:1001–1010.
- 30 Lo WK, Chan WW: Proton pump inhibitor use and the risk of small intestinal bacterial overgrowth: a meta-analysis. *Clin Gastroenterol Hepatol* 2013;11:483–490.
- 31 Deshpande A, Pasupuleti V, Thota P, Pant C, Mapara S, Hassan S, Rolston DD, Sferra TJ, Hernandez AV: Acid-suppressive therapy is associated with spontaneous bacterial peritonitis in cirrhotic patients: a meta-analysis. *J Gastroenterol Hepatol* 2013;28:235–242.
- 32 Fraser LA, Leslie WD, Targownik LE, Papaioannou A, Adachi JD, CaMos Research Group: The effect of proton pump inhibitors on fracture risk: report from the Canadian Multicenter Osteoporosis Study. *Osteoporos Int* 2013;24:1161–1168.
- 33 Quasdorff M, Mertens J, Dinter J, Steffen HM: Recurrent hypomagnesemia with proton-pump inhibitor rechallenge. *Ann Intern Med* 2011;155:405–407.
- 34 Sierra F, Suarez M, Rey M, Vela MF: Systematic review: proton pump inhibitor-associated acute interstitial nephritis. *Aliment Pharmacol Ther* 2007;26:545–553.
- 35 Keszthelyi D, Jansen SV, Schouten GA, de Kort S, Scholtes B, Engels LG, Masclee AA: Proton pump inhibitor use is associated with an increased risk for microscopic colitis: a case-control study. *Aliment Pharmacol Ther* 2010;32:1124–1128.
- 36 Merwat SN, Spechler SJ: Might the use of acid suppressive medications predispose to the development of eosinophilic esophagitis? *Am J Gastroenterol* 2009;104:1897–1902.
- 37 Dunn SP, Steinhubl SR, Bauer D, Charnigo RJ, Berger PB, Topol EJ: Impact of proton pump inhibitor therapy on the efficacy of clopidogrel in the CAPRIE and CREDO trials. *J Am Heart Assoc* 2013;2:e004564.
- 38 Charlot M, Ahlehoff O, Norgaard ML, Jørgensen CH, Sørensen R, Abildstrøm SZ, Hansen PR, Madsen JK, Køber L, Torp-Pedersen C, Gislason G: Proton-pump inhibitors are associated with increased cardiovascular risk independent of clopidogrel use: a nationwide cohort study. *Ann Intern Med* 2010;153:378–386.
- 39 El-Serag HB, Aguirre TV, Davis S, Kuebel M, Bhattacharyya A, Sampliner RE: Proton pump inhibitors are associated with reduced incidence of dysplasia in Barrett's esophagus. *Am J Gastroenterol* 2004;99:1877–1883.
- 40 Nguyen DM, El-Serag HB, Henderson L, Stein D, Bhattacharyya A, Sampliner RE: Medication usage and the risk of neoplasia in patients with Barrett's esophagus. *Clin Gastroenterol Hepatol* 2009;7:1299–1304.
- 41 Hillman LC, Chiragakis L, Shadbolt B, Kaye GL, Clarke AC: Proton-pump inhibitor therapy and the development of dysplasia in patients with Barrett's oesophagus. *Med J Aust* 2004;180:387–391.
- 42 Kastelein F, Spaander MC, Steyerberg EW, Biermann K, Valkhoff VE, Kuipers EJ, Bruno MJ, ProBar Study Group: Proton pump inhibitors reduce the risk of neoplastic progression in patients with Barrett's esophagus. *Clin Gastroenterol Hepatol* 2013;11:382–388.
- 43 DeMeester SR, DeMeester TR: Columnar mucosa and intestinal metaplasia of the esophagus. Fifty years of controversy. *Ann Surg* 2000;231:303–321.

- 44 Katz D, Rothstein R, Schned A, Dunn J, Seaver K, Antonioli D: The development of dysplasia and adenocarcinoma during endoscopic surveillance of Barrett's esophagus. *Am J Gastroenterol* 1998;93:536-541.
- 45 Oberg S, Wenner J, Johansson J, Walther B, Willen R: Barrett esophagus: risk factors for progression to dysplasia and adenocarcinoma. *Ann Surg* 2005;242:49-54.
- 46 Richter JE: Gastroesophageal reflux disease treatment: side effects and complications of fundoplication. *Clin Gastroenterol Hepatol* 2013;11:465-471.
- 47 Spechler SJ, Lee E, Ahnen D, Goyal RK, Hirano I, Ramirez F, Raufman JP, Sampliner R, Schnell T, Sontag S, Vlahcevic ZR, Young R, Williford W: Long-term outcome of medical and surgical treatments for gastroesophageal reflux disease. Follow-up of a randomized controlled trial. *JAMA* 2001;285:2331-2338.
- 48 Parrilla P, Martínez de Haro LF, Ortiz A, Munitiz V, Molina J, Bermejo J, Canteras M: Long-term results of a randomized prospective study comparing medical and surgical treatment of Barrett's esophagus. *Ann Surg* 2003;237:291-298.
- 49 Corey KE, Schmitz SM, Shaheen NJ: Does a surgical antireflux procedure decrease the incidence of esophageal adenocarcinoma in Barrett's esophagus? A meta-analysis. *Am J Gastroenterol* 2003;98:2390-2394.
- 50 Chang EY, Morris CD, Seltman AK, O'Rourke RW, Chan BK, Hunter JG, Jobe BA: The effect of antireflux surgery on esophageal carcinogenesis in patients with Barrett esophagus: a systematic review. *Ann Surg* 2007;246:11-21.
- 51 Ye W, Chow WH, Lagergren J, Yin L, Nyren O: Risk of adenocarcinoma of the esophagus and gastric cardia in patients with gastroesophageal reflux diseases and after antireflux surgery. *Gastroenterology* 2001;121:1286-1293.
- 52 Tran T, Spechler SJ, El-Serag HB: Fundoplication and the risk of cancer in gastroesophageal reflux disease: a veterans affairs cohort study. *Am J Gastroenterol* 2005;100:1002-1008.
- 53 Lagergren J, Ye W, Lagergren P, Lu Y: The risk of esophageal adenocarcinoma after antireflux surgery. *Gastroenterology* 2010;138:1297-1301.
- 54 Drewitz DJ, Sampliner RE, Garewal HS: The incidence of adenocarcinoma in Barrett's esophagus: a prospective study of 170 patients followed 4.8 years. *Am J Gastroenterol* 1997;92:212-215.
- 55 Shaheen NJ, Crosby MA, Bozymski EM, Sandler RS: Is there publication bias in the reporting of cancer risk in Barrett's esophagus? *Gastroenterology* 2000;119:333-338.
- 56 Desai TK, Krishnan K, Samala N, Singh J, Cluley J, Perla S, Howden CW: The incidence of oesophageal adenocarcinoma in non-dysplastic Barrett's oesophagus: a meta-analysis. *Gut* 2012;61:970-976.
- 57 Wani S, Falk G, Hall M, Gaddam S, Wang A, Gupta N, Singh M, Singh V, Chuang KY, Boolchand V, Gavini H, Kuczynski J, Sud P, Reddymasu S, Bansal A, Rastogi A, Mathur SC, Young P, Cash B, Lieberman DA, Sampliner RE, Sharma P: Patients with nondysplastic Barrett's esophagus have low risks for developing dysplasia or esophageal adenocarcinoma. *Clin Gastroenterol Hepatol* 2011;9:220-227.
- 58 Bhat S, Coleman HG, Yousef F, Johnston BT, McManus DT, Gavin AT, Murray LJ: Risk of malignant progression in Barrett's esophagus patients: results from a large population-based study. *J Natl Cancer Inst* 2011;103:1049-1057.
- 59 Hvid-Jensen F, Pedersen L, Drewes AM, Sørensen HT, Funch-Jensen P: Incidence of adenocarcinoma among patients with Barrett's esophagus. *N Engl J Med* 2011;365:1375-1383.