

# Deep Brain Stimulation for Tremor: Is There a Common Structure?

Michael Fiechter<sup>a</sup> Andreas Nowacki<sup>a</sup> Markus F. Oertel<sup>a</sup> Jens Fichtner<sup>a</sup>  
Ines Debove<sup>b</sup> M. Lenard Lachenmayer<sup>b</sup> Roland Wiest<sup>c</sup> Claudio L. Bassetti<sup>b</sup>  
Andreas Raabe<sup>a</sup> Alain Kaelin-Lang<sup>b</sup> Michael W. Schüpbach<sup>b</sup> Claudio Pollo<sup>a</sup>

Departments of <sup>a</sup>Neurosurgery and <sup>b</sup>Neurology, and <sup>c</sup>Institute for Diagnostic and Interventional Neuroradiology, Inselspital, Bern University Hospital and University of Bern, Bern, Switzerland

## Keywords

Deep brain stimulation · Dentato-rubro-thalamic tract · Tremor · Subthalamic nucleus · Thalamic ventral intermediate nucleus

## Abstract

**Background:** Subthalamic nucleus (STN) stimulation has been recognized to control resting tremor in Parkinson disease. Similarly, thalamic stimulation (ventral intermediate nucleus; VIM) has shown tremor control in Parkinson disease, essential, and intention tremors. Recently, stimulation of the posterior subthalamic area (PSA) has been associated with excellent tremor control. Thus, the optimal site of stimulation may be located in the surrounding white matter. **Aims:** The objective of this work was to investigate the area of stimulation by determining the contact location correlated with the best tremor control in STN/VIM patients. **Methods:** The mean stimulation site and related volume of tissue activated (VTA) of 25 tremor patients (STN or VIM) were projected on the Morel atlas and compared to stimulation sites from other tremor studies. **Results:** All patients showed a VTA that covered  $\geq 50\%$  of the area superior and medial to the STN or inferior to the VIM. Our stimulation areas suggest involvement of the more lateral and superior part of the dentato-

rubro-thalamic tract (DRTT), whereas targets described in other studies seem to involve the DRTT in its more medial and inferior part when it crosses the PSA. **Conclusions:** According to anatomical and diffusion tensor imaging data, the DRTT might be the common structure stimulated at different portions within the PSA/caudal zona incerta.

© 2017 S. Karger AG, Basel

## Introduction

Deep brain stimulation (DBS) is a surgical technique that is effective for treating motor symptoms of Parkinson disease (PD) and essential tremor (ET) [1]. DBS of the subthalamic nucleus (STN) and thalamic ventral intermediate nucleus (VIM) have shown to reduce tremor resulting from PD as well as ET [2–4]. However, the optimal location of stimulation to improve tremor is still debated.

Retrospective studies on electrode position in the VIM indicated that some effective stimulation sites were below the thalamus [5, 6]. Similarly, studies that aimed to stimulate the STN reported efficacy at stimulation sites above

M.F. and A.N. contributed equally to this work.

and medial to the STN [7, 8]. Furthermore, stimulation of the posterior subthalamic area (PSA) or the caudal zona incerta (Zi) appeared advantageous for tremor control [9, 10].

In this study, we investigate the position of the active contacts in tremor patients with PD or ET implanted in either the STN or the VIM and correlated with the best control of tremor. We evaluate the area of stimulation considering the related volume of tissue activated (VTA) in each target. Furthermore, we describe and discuss the possible common anatomical area and structure involved in the control of tremor, according to the relevant literature.

## Methods

### Study Design and Patient Population

This retrospective cohort trial was performed at a single medical center (Inselspital, Bern University Hospital). We recruited all patients with tremor-dominant PD or ET ( $\geq 18$  years) who underwent DBS in the VIM or STN from 2008 until mid-2012.

Twenty-eight patients with tremor-associated PD and 12 patients with ET were recruited. Due to incomplete data sets (missing pre- or post-DBS imaging or insufficient clinical data), 10 patients with PD and 5 patients with ET had to be excluded. Therefore, 18 patients with PD and 7 patients with ET underwent further investigation. Three of the 18 patients with PD were implanted in the VIM because of tremor-dominant Parkinsonism.

Authorization to perform this study was granted by the institutional review board (local ethics committee, KEK-052/14). The need to obtain written informed consent for use of the patients' clinical and imaging data for research purposes was waived because of the purely retrospective nature of the study.

### Position of Active Electrode Contacts, Stimulation Parameters, and Calculation of VTA

All patients underwent a routine postoperative stereotactic computed tomography, which was coregistered with the preoperative 3T T2-weighted magnetic resonance imaging scan using iPlan Net software (Brainlab AG, Feldkirchen, Germany) to determine the position of the active electrode contacts related to the MCP (midcommissural point) between the AC (anterior commissure)-PC (posterior commissure) referential. For each patient, stimulation parameters, including the number of active contacts, voltage, pulse width, frequency, and impedance, were obtained after a follow-up period of 5–22 months. For patients with bipolar stimulation the cathode was considered the active contact. Finally, the VTA was obtained from the newly developed Optivise software (Medtronic Inc., Minneapolis, MN, USA). The calculation of the VTA is based on the pioneering work performed by McIntyre and coworkers on the computed finite element model of DBS and further retrieved in other groups [11–14]. The position of the mean stimulation site and the related VTA were projected on an axial and sagittal slice of the Morel stereotactic atlas [15]. On the same atlas slices, the stimulation sites obtained from other published studies were also projected.

**Table 1.** Position of active contacts (relative to the MCP)

	STN, mm	VIM, mm	<i>p</i> value
LAT	12.8 $\pm$ 1.1	14.3 $\pm$ 1.6	<0.001
AP	-2.0 $\pm$ 1.7	-5.0 $\pm$ 0.9	<0.001
VERT	-0.8 $\pm$ 1.6	0.9 $\pm$ 1.2	<0.001

Values are the mean  $\pm$  SD. MCP, midcommissural point; STN, subthalamic nucleus; VIM, ventral intermediate nucleus; LAT, lateral; AP, anteroposterior; VERT, vertical.

### Evaluation of Therapeutic Effect

Each patient routinely underwent clinical examination 1–6 months before and 5–22 months after DBS surgery. DBS parameters were stable for at least 3 months before the last follow-up. The therapeutic efficacy in patients implanted in the STN was measured by the Unified Parkinson's Disease Rating Scale (UPDRS) III [16], and in VIM patients it was measured by the Fahn-Tolosa-Marin Tremor Rating Scale (FTMS) [17]. Only rating scores with preoperative and postoperative off-medication conditions were considered for further analysis.

### Statistical Analysis

The data were analyzed with descriptive/parametric statistics using Statistical Package for the Social Sciences (SPSS) software (version 20, IBM Corp., New York, NY, USA). The Shapiro-Wilk test was used to test for a normal distribution of different data sets. The Student *t* test was thereafter applied to compare the location of stimulation in the 2 different populations. An analysis of the therapeutic effects of DBS, as measured by the UPDRS III (in STN) or FTMS (in VIM) rating scales, was performed by the Wilcoxon signed-rank test. A *p* value <0.05 was considered statistically significant.

## Results

Each of the 15 STN patients were bilaterally stimulated, which allowed analysis of 30 stimulation electrodes (mean age 59  $\pm$  9 years, 67% males). Among the VIM patients, 3 were unilaterally stimulated (unilateral tremor symptoms) and 7 were bilaterally stimulated, allowing investigation of 17 stimulation electrodes (mean age 71  $\pm$  11 years, 90% males).

The mean coordinates (in mm) of the active contacts relative to the MCP in patients implanted in the STN were: lateral (LAT) = 12.8  $\pm$  1.1, anteroposterior (AP) = -2.0  $\pm$  1.7, and vertical (VERT) = -0.8  $\pm$  1.6; and for those implanted in the VIM were: LAT = 14.3  $\pm$  1.6, AP = -5.0  $\pm$  0.9, VERT = 0.9  $\pm$  1.2 (Table 1, *p* < 0.001).

The value of the mean stimulation parameters (voltage, pulse width, frequency, and impedance) of the active electrode contacts in STN patients were 2.6  $\pm$  0.7 V, 62.0  $\pm$  7.7  $\mu$ s, 135.7  $\pm$  18.4 Hz, and 1491.5  $\pm$  553.7  $\Omega$ , res-

pectively. The value of the mean stimulation parameters of the active electrode contacts in patients implanted in the VIM were  $3.0 \pm 0.7$  V,  $180.0 \pm 40.0$   $\mu$ s,  $141.5 \pm 19.7$  Hz, and  $1,528.4 \pm 1,104.5$   $\Omega$ , respectively. The mean ( $\pm$ SD) VTA diameter in STN patients was  $4.8 \pm 1.1$  mm versus  $5.8 \pm 1.8$  mm in VIM patients.

Figure 1 illustrates the projection of the mean VTAs on axial and sagittal slices of the Morel stereotactic atlas in relation to the dentato-rubro-thalamic tract (DRTT; named fasciculus cerebello-thalamicus, *fct*, in the atlas) [15]. When projected separately all the patients revealed a VTA covering  $\geq 50\%$  of the area superior to the STN or inferior to the VIM.

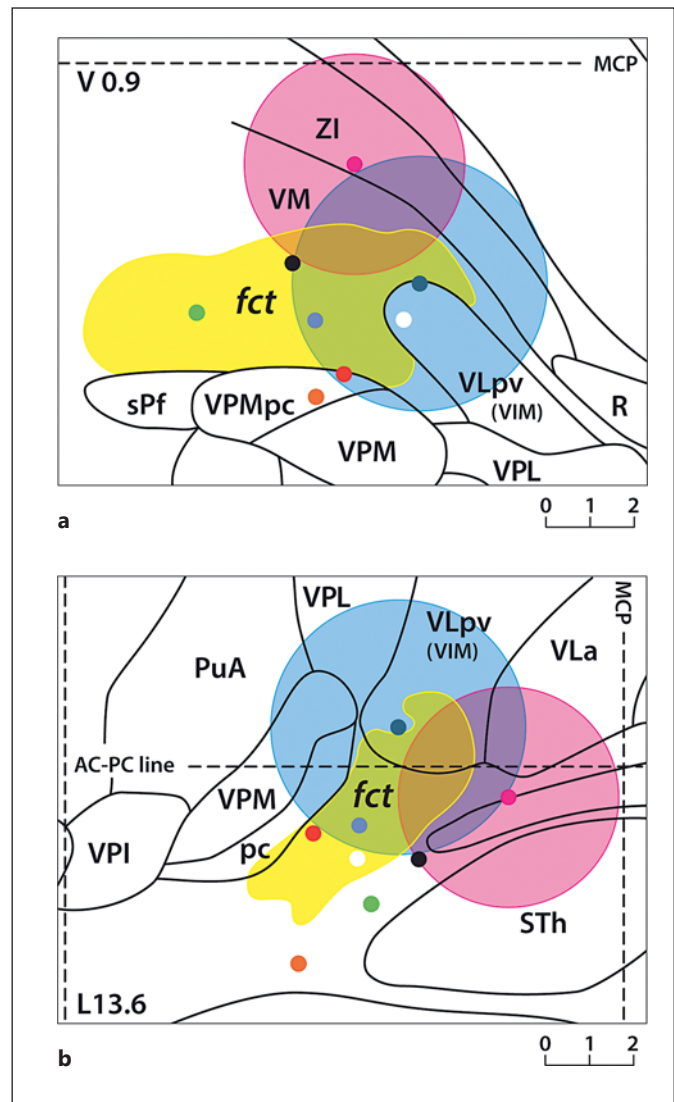
The mean ( $\pm$ SD) UPDRS III scores in STN patients before and after DBS were  $38.5 \pm 10.9$  and  $21.3 \pm 10.0$ , respectively (improvement of 45%,  $p = 0.001$ ; Fig. 2a). Furthermore, the mean pre- and postoperative UPDRS III scores for resting tremor were  $5.3 \pm 3.6$  and  $1.5 \pm 2.1$ , respectively ( $p = 0.003$ ; Fig. 2b), and  $2.5 \pm 1.3$  and  $0.9 \pm 0.9$ , respectively, for action tremor ( $p = 0.003$ ; Fig. 2b). Thus, resting and action tremors improved by 72 and 64%, respectively.

The mean ( $\pm$ SD) FTMS scores in all VIM patients were  $22.6 \pm 7.6$  before and  $10.5 \pm 6.7$  after DBS (improvement of 54%,  $p = 0.005$ ; Fig. 2c). Moreover, the mean ( $\pm$ SD) scores of pre- and postoperative subtypes of tremor were  $5.7 \pm 3.6$  and  $1.4 \pm 2.5$  for resting tremor ( $p = 0.008$ ; Fig. 2d),  $8.7 \pm 2.9$  and  $3.8 \pm 2.5$  for postural tremor ( $p = 0.007$ ; Fig. 2d), and  $8.2 \pm 1.7$  and  $5.3 \pm 2.5$  for intentional tremor ( $p = 0.015$ ; Fig. 2d). Thus, the clinical improvements in resting, postural, and intentional tremors were 75, 56, and 35%, respectively.

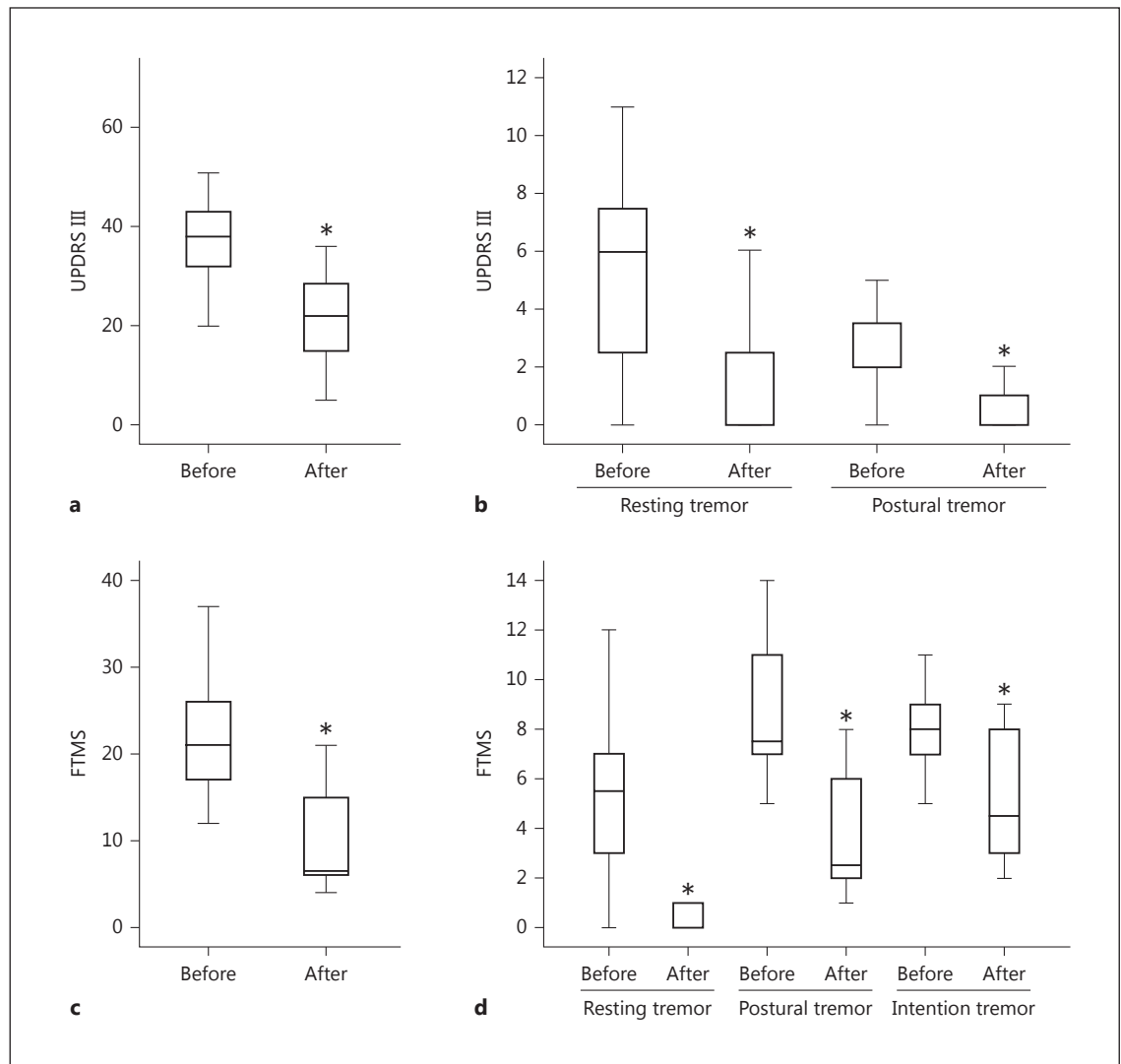
In a subgroup analysis (VIM patients with unilateral DBS,  $n = 3$ ), the mean ( $\pm$ SD) FTMS scores were  $75.0 \pm 7.0$  before and  $42.0 \pm 7.5$  after DBS (improvement of 44%). The mean ( $\pm$ SD) scores of pre- and postoperative subtypes of tremor were  $22.0 \pm 2.5$  and  $7.0 \pm 3.2$  for resting tremor,  $27.0 \pm 3.5$  and  $14.0 \pm 3.5$  for postural tremor, and  $26.0 \pm 1.2$  and  $21.0 \pm 2.0$  for intention tremor. Thus, the clinical improvements in resting, postural, and intention tremors were 68, 48, and 19%, respectively (sample size too small for a reliable statistical analysis).

## Discussion

In the present study, the mean location of the stimulated contacts and the VTA analysis suggests that the site of stimulation correlated with the best control of tremor in our STN DBS patients covers the superior border of the



**Fig. 1.** Projection of the 2 mean stimulation coordinates and VTA in patients implanted in the STN (pink point and sphere) and VIM of the thalamus (blue point and sphere). Both axial (a) and sagittal (b) slices reveal that the DRTT (named fasciculus cerebello-thalamicus, *fct*; yellow area) is partially included by the mean VTA in both patient groups. The mean stimulation coordinates of Plaha et al. [23] (black point), Hamel et al. [10] (red point), Sandvik et al. [5] (gray point), Kitagawa et al. [26] (green point), Carrillo-Ruiz et al. [22] (orange point), and Plaha et al. [24] (white point) are depicted in both projections (stimulation coordinates are given in Table 2). The mean stimulation coordinates from Herzog et al. [39] were not applicable. Images are adapted from the Morel stereotactic atlas [15]. MCP, midcommissural point; ZI, zona incerta; VM, ventral medial nucleus; sPf, subparafascicular nucleus; VPMpc, ventral posterior medial nucleus, parvocellular division; VPM, ventral posterior medial nucleus; VLpv, ventral lateral posterior nucleus, ventral division; VPL, ventral posterior lateral nucleus; R, reticular thalamic nucleus; PuA, anterior pulvinar; VPI, ventral posterior inferior nucleus; pc, posterior commissure; VLa, ventral lateral anterior nucleus; STh, subthalamic nucleus.



**Fig. 2.** Therapeutic effect in patients implanted in the STN (**a, b**) and VIM (**c, d**). The overall therapeutic efficacy in STN patients is given in **a** as quantified by the UPDRS III ( $p = 0.001$ ). The improvement of subtypes of tremor in STN-implanted patients is shown in **b** ( $p = 0.003$  for each tremor subtype). In VIM-implant-

ed patients the overall improvement according to the FTMS is given in **c** ( $p = 0.005$ ). The subtypes of tremor in VIM-stimulated patients are shown for resting ( $p = 0.008$ ), postural ( $p = 0.007$ ), and intentional tremor ( $p = 0.015$ ) in **d**. Statistically significant differences/improvements are marked with an asterisk.

STN, an area located proximal and medial to the anatomical limits of the nucleus. Similarly, the mean site of stimulation correlated with the best control of tremor in our VIM DBS cohort covers not only the inferior and posterior part of the VIM, but also an area located distal to the anatomical borders of the VIM.

The anatomical structure common to these 2 different stimulation areas is the PSA, located distal to the inferior border of the thalamus, between the red nucleus (medially) and STN (laterally) [18]. It includes the Zi, the fields

of Forel, the prelemniscal radiation, and a part of the cerebellothalamic tract. The Zi is a small cellular structure located proximal to the STN, lying between the fields of Forel. The fasciculus lenticularis (or Forel field H2) and the ansa lenticularis compose the pallidothalamic tract. Both fiber tracts merge into the fasciculus thalamicus (or Forel field H1) dorsally and medially to the STN before entering the thalamus [19]. The cerebellothalamic tract or DRTT forms the main cerebellar efferent by interconnecting cerebellar nuclei (emboliform, globose, and den-

**Table 2.** Overview of active contacts in tremor patients (relative to the MCP) and the clinical improvement of tremor

Study, year	Target	LAT, mm	AP, mm	VERT, mm	Improvement, %
Plaha [23], 2004	PSA (Zi)	11.5±0.5	-4.5±0.4	-2.2±0.4	80.1
Hamel [10], 2007	VIM	12.7±1.4	-7.0±1.6	-1.5±2.0	67.6 to 72.6
Sandvik [5], 2012	PSA (Zi)	12.0±1.8	-5.8±1.6	-1.7±2.6	≥90
Kitagawa [26], 2005	PSA (Zi)	10.5±1.2	-5.6±1.2	-3.2±1.1	78.3
Carrillo-Ruiz [22], 2012	Raprl	12 (11 to 13)	-7.5 (-6 to -9)	-4.5 (-4 to -5)	68 to 100
Present study	STN	12.8±1.1	-2.0±1.7	-0.8±1.6	64 <sup>1</sup> ; 72 <sup>2</sup>
Plaha [24], 2006	cZi	14.0±1.6	-5.8±1.5	-2.1±1.1	93
Herzog [39], 2007	PSA (Zi)	na	na	na	55.9
Present study	VIM	14.3±1.6	-5.0±0.9	0.9±1.2	75 <sup>1</sup> ; 56 <sup>3</sup> ; 35 <sup>4</sup>

LAT, AP, and VERT values are the mean ± SD. MCP, midcommissural point; LAT, lateral; AP, anteroposterior; VERT, vertical; PSA, posterior subthalamic area; Raprl, prelemniscal radiations; Zi, zona incerta; cZi, caudal zona incerta; STN, subthalamic nucleus; VIM, ventral intermediate nucleus; na, not applicable.

<sup>1</sup> Resting tremor. <sup>2</sup> Action tremor. <sup>3</sup> Postural tremor. <sup>4</sup> Intention tremor.

tate nuclei) and projecting through the superior cerebellar peduncle into the red nucleus and then the ventrolateral thalamus [19–21]. From the red nucleus to the thalamus, the DRTT crosses the Zi from posterior to anterior when it goes from medial to lateral and from inferior to superior. It ends in the nucleus ventrooralis posterior and VIM, according to Hassler nomenclature.

The prelemniscal radiation is a compact fiber bundle located anterior to the medial lemniscus. It actually contains fibers from different origins, including axons from the DRTT crossing from pallidum to motor thalamus. It can therefore be seen as part of the DRTT between the red nucleus and the thalamus and follows the same trajectory in the PSA (see above) [22].

DBS of the PSA has previously been investigated and shown to provide a significant effect on tremor control [5, 6, 9, 23, 24]. Sandvik et al. [5] reported that stimulation of the PSA in ET patients produced an improvement of tremor in ≥90% of their cases. Plaha et al. [24] refer to this area using the term caudal Zi to distinguish between a caudal and a more rostral part. This group has performed pioneering work on stimulation of the PSA/caudal Zi. They reported an 80.1% improvement of tremor scores in ET patients [23]. Likewise, in PD patients, electrical stimulation of the caudal Zi improved tremor by 93% and was reported to be superior to STN DBS [24]. They also achieved successful tremor control in other tremors, such as Holmes tremor and dystonic tremor [9]. Hamel et al. [10] reported successful tremor control in 11 patients with intention tremor, including ET through stimulation of the subthalamic area. Other studies have shown that

parkinsonian tremor could be significantly improved by stimulation of the PSA [25, 26].

In the current study, the mean active contact in the VIM target had similar AP and LAT coordinates as the last-mentioned study, although our VERT coordinate was on average 3.0 mm more proximal. This difference in the VERT axis was expected, as the primary purpose in this series was to implant the VIM and not the Zi. Furthermore, given the mean VTA diameter in these patients and taking into account the fact that axons are stimulated at a lower intensity than neurons, we believe that our stimulation area overlaps the PSA.

In our STN cohort the LAT and VERT coordinates of the best stimulation point were comparable to those reported by Plaha et al. [23], as well as by Sandvik et al. [5], and Hamel et al. [10]. Interestingly, in the last paper, the authors intended to target the VIM. Our AP coordinate was 2.5–5 mm more anterior. This difference in the AP axis was also expected, as the STN was primarily targeted. Given the mean VTA diameter in these patients, we also believe that our mean stimulation site overlaps the area of stimulation described in Plaha et al. [23]. These different mean targets are summarized in Table 2 and also reported on the Morel atlas (Fig. 1).

While numerous studies have suggested that the stimulation site correlated with the best clinical results in PD patients is located in the superior and lateral part of the STN [27–30], PSA DBS in PD patients have also suggested a positive effect on rigidity and bradykinesia. These findings should, however, be taken cautiously since the experience with PSA DBS is limited. They were per-

formed on small numbers of patients and no randomized studies are available. Moreover, disabling side effects may be associated with the stimulation of this area. Worsening bradykinesia and freezing have been reported and possibly correlate with the stimulation of the pallidothalamic fibers [31–33]. Similarly, dysarthria and postural instability have also been described and correlated to the possible diffusion of current to the cerebellothalamic tract and on the other hand by blocking levodopa effects [34]. Karlsson et al. [35, 36] reported a negative effect on voice intensity and speech articulation of PSA/caudal Zi compared with STN stimulation. Finally, ataxia has been reported when suprathreshold stimulation of the PSA was performed [20]. The assessment of potential side effects of PSA/caudal Zi stimulation was beyond the purpose of this study, as this area was not primarily and specifically intended to be stimulated. This issue should be addressed in further studies in order to identify the best stimulation site within the PSA and with respect to the DRTT.

Previous studies have also suggested that tremor control could be achieved through the stimulation of the cerebellothalamic pathways [37, 38]. Moreover, Plaha et al. [23] and Herzog et al. [39] suggested that tremor control in the posterior subthalamic region might be related to the stimulation of the DRTT in a deeper position where it crosses the PSA/caudal Zi. Similarly, Carrillo-Ruiz et al. [22] and Herzog et al. [39] postulated that a successful tremor control was achieved through the stimulation of the prelemniscal radiation, which contains fibers of the DRTT. Calabrese et al. [38] recently showed a close relationship between electrode position and DRTT on postmortem tractography studies in ET patients. Finally, Coenen et al. [40–42] nicely demonstrated that tremor control could be achieved through the stimulation of the DRTT directly visualized on diffusion tensor imaging (DTI) reconstruction of the DRTT and even proposed an individual targeting.

Based on the Morel atlas, Gallay et al. [19] showed that the DRTT (called the fasciculus cerebello-thalamicus in their study) crosses the PSA/caudal Zi between the red nucleus and the STN. Recent studies based on individual targeting of the DRTT using DTI and tractography techniques also support the hypothesis that stimulation of the DRTT plays an important role. Interestingly, despite the primarily intended targeting of the STN and the VIM, we were able to show that tremor control was better achieved when the electrodes and VTA were located slightly above and medial to the STN, or slightly distal to the VIM, respectively, which in our opinion supports the concept that a common structure (i.e., the DRTT) is involved at 2 different anatomical places in these 2 groups.

According to the Morel atlas, our comprehensive review of the different previously published targets also shows some spatial variability around or inside the DRTT and points out that although the DRTT is commonly targeted in these papers, the optimal target is still not clarified in this challenging region. It probably represents a balance between the efficacy on tremor control and the side effects (dysarthria, ataxia, and gait imbalance). This particular point could be specifically addressed in a further study.

Nevertheless, according to the Morel atlas, our mean targets and respective VTAs suggest that our stimulation area involves the more lateral and superior part of the DRTT, whereas targets described in other studies seem to involve the DRTT in its more medial and inferior part when it crosses the PSA.

This study proposes a retrospective and uncontrolled analysis of the best stimulation point in a limited number and a mixed cohort of patients with PD or ET. Although the pathophysiology of tremor is different in PD and ET and involves different structures, we found a significant improvement in tremor symptoms in both our cohorts of patients as well as in both VIM and STN targets. This suggests that a common structure may be involved in both diseases, particularly regarding the control of tremor, and points out the mechanism of effect of DBS on tremor, as previously mentioned by Hanson et al. [43].

In addition, the assessment of tremor in STN patients was conducted using the UPDRS, which is validated for PD, and in VIM-targeted patients with the FTMS, widely used for ET. Due to the clinical characteristics of the tremor in each condition, FTMS may not be the finest tool with which to assess tremor in PD patients in order to compare their scores to those of ET patients. However, this has been done in the literature [9, 44].

Furthermore, we were not able to directly correlate the DTI-based identification of the DRTT and clinical outcome (patient-specific approach), which would certainly strengthen the hypothesis that tremor control is achieved through the stimulation of the DRTT. Unfortunately, a preoperative DTI sequence was not performed routinely before 2012 in our institution. Moreover, the correlation between the proximity of the DTI-based identification of the DRTT and clinical outcome is also a matter of debate in the literature [21] and is due to some technical limitations of the DTI to accurately show the DRTT (DTI assumptions on diffusion, signal to noise ratio, coregistration accuracy, etc.). For this reason, we found that the projection of our mean stimulation site on the Morel atlas was appropriate as it provides a precise

anatomical location of the DRTT. Improvement of imaging techniques and analysis should allow identification of the DRTT with a higher accuracy, and therefore allow a more reliable correlation in each patient. We did not correlate the position of the active contact to the position of the DRTT in each patient, as a preoperative DTI sequence was not performed routinely before 2012 in our institution. The accuracy and reliability of DTI to identify the DRTT may also be questioned, as several parameters may have an impact on its exact location, as was mentioned by Schlaier et al. [21]. Moreover, the VTA calculation is based on finite element models of electrical propagation around the electrode and provides an approximation of the real VTA in each individual patient [11, 12]. As an example, our mean VTA seems also to cover the ventral posterior lateral nucleus (VPL) in the VIM cohort. Actually, none of the patients had persisting paresthesia from DBS stimulation. We believe that either the VPL nucleus is not included in our VIM DBS patients or there may be a habituation of the VPL to electrical stimulation. Nevertheless, computational models of DBS have shown a good correlation with an improvement of symptoms and reduction of adverse effects [13, 14, 27, 45]. Considering the possible variations of the localization of the DRTT, also described in this atlas, we believe that the DRTT in the PSA/caudal Zi could be the common structure stimulated at different places in both our cohorts as well as in the other mentioned studies, as illustrated in Figure 1.

## References

- Schuurman PR, Bosch DA, Bossuyt PM, Bonsel GJ, van Someren EJ, de Bie RM, Merkus MP, Speelman JD: A comparison of continuous thalamic stimulation and thalamotomy for suppression of severe tremor. *N Engl J Med* 2000;342:461–468.
- Deuschl G, Schade-Brittinger C, Krack P, Volkmann J, Schafer H, Botzel K, Daniels C, Deutschlander A, Dillmann U, Eisner W, Gruber D, Hamel W, Herzog J, Hilker R, Klebe S, Kloss M, Koy J, Krause M, Kupsch A, Lorenz D, Lorenz S, Mehdorn HM, Moringlane JR, Oertel W, Pinski MO, Reichmann H, Reuss A, Schneider GH, Schnitzler A, Steude U, Sturm V, Timmermann L, Tronnier V, Trottenberg T, Wojtecki L, Wolf E, Poewe W, Voges J; German Parkinson Study Group, Neurostimulation Section: A randomized trial of deep-brain stimulation for Parkinson's disease. *N Engl J Med* 2006;355:896–908.
- Benabid AL, Chabardes S, Mitrofanis J, Pollak P: Deep brain stimulation of the subthalamic nucleus for the treatment of Parkinson's disease. *Lancet Neurol* 2009;8:67–81.
- Deuschl G, Raethjen J, Hellriegel H, Elble R: Treatment of patients with essential tremor. *Lancet Neurol* 2011;10:148–161.
- Sandvik U, Koskinen LO, Lundquist A, Blomstedt P: Thalamic and subthalamic deep brain stimulation for essential tremor: where is the optimal target? *Neurosurgery* 2012;70:840–846.
- Blomstedt P, Sandvik U, Tisch S: Deep brain stimulation in the posterior subthalamic area in the treatment of essential tremor. *Mov Disord* 2010;25:1350–1356.
- Sweet JA, Walter BL, Gunalan K, Chaturvedi A, McIntyre CC, Miller JP: Fiber tractography of the axonal pathways linking the basal ganglia and cerebellum in Parkinson disease: implications for targeting in deep brain stimulation. *J Neurosurg* 2014;120:988–996.
- Lukins TR, Tisch S, Jonker B: The latest evidence on target selection in deep brain stimulation for Parkinson's disease. *J Clin Neurosci* 2014;21:22–27.
- Plaha P, Khan S, Gill SS: Bilateral stimulation of the caudal zona incerta nucleus for tremor control. *J Neurol Neurosurg Psychiatry* 2008;79:504–513.
- Hamel W, Herzog J, Kopper F, Pinski M, Weinert D, Muller D, Krack P, Deuschl G, Mehdorn HM: Deep brain stimulation in the subthalamic area is more effective than nucleus ventralis intermedialis stimulation for bilateral intention tremor. *Acta Neurochir (Wien)* 2007;149:749–758.

## Conclusions

In PD or ET patients, treatment for tremor with DBS in the STN or VIM, or the best stimulation point, together with the mean related VTA seems to cover a stimulation area located inferior to the thalamus and superior and medial to the STN, anatomically corresponding to the PSA. According to anatomical and DTI data, the stimulation area appears to involve the DRTT in its lateral, superior, and anterior aspect in the PSA, compared to other studies where the DRTT appears to be stimulated more medially, inferiorly, and posteriorly. With regard to these different stimulation sites, the DRTT might be a common structure involved at different sites in the PSA. Our results, together with those obtained from the relevant literature, open the door for a future prospective study to identify the best stimulation site within the PSA and related to the DRTT in order to avoid potential disabling side effects that might detract from the actual improvement.

## Acknowledgments

We would like to acknowledge Mrs. Ruth Tschirren, who supported the clinical data collection. Furthermore, we thank Alexander Stibal, MD, who was clinically involved as a DBS surgeon in patient care.

## Disclosure Statement

There are no conflicts of interest or funding sources to disclose.

- 11 Golestanirad L, Izquierdo AP, Graham SJ, Mosig JR, Pollo C: Document effect of realistic modeling of deep brain stimulation on the prediction of volume of activated tissue. *Prog Electromagnet Res* 2012;126:1–16.
- 12 Walckiers G, Fuchs B, Thiran JP, Mosig JR, Pollo C: Influence of the implanted pulse generator as reference electrode in finite element model of monopolar deep brain stimulation. *J Neurosci Methods* 2010;186:90–96.
- 13 Butson CR, Cooper SE, Henderson JM, McIntyre CC: Patient-specific analysis of the volume of tissue activated during deep brain stimulation. *Neuroimage* 2007;34:661–670.
- 14 Maks CB, Butson CR, Walter BL, Vitek JL, McIntyre CC: Deep brain stimulation activation volumes and their association with neurophysiological mapping and therapeutic outcomes. *J Neurol Neurosurg Psychiatry* 2009;80:659–666.
- 15 Morel A, Magnin M, Jeanmonod D: Multiarchitectonic and stereotactic atlas of the human thalamus. *J Comp Neurol* 1997;387:588–630.
- 16 Stacy MA, Elble RJ, Ondo WG, Wu SC, Hulihan J; TRS Study Group: Assessment of interrater and intrarater reliability of the Fahn-Tolosa-Marin Tremor Rating Scale in essential tremor. *Mov Disord* 2007;22:833–838.
- 17 Fahn S, Tolosa E, Conception M: Clinical rating scale for tremor; in Jankovic J, Tolosa E (eds): *Parkinson's Disease and Movement Disorders*, ed 2. Munich, Urban & Schwarzenberg, 1988, pp 225–234.
- 18 Blomstedt P, Sandvik U, Fytagoridis A, Tisch S: The posterior subthalamic area in the treatment of movement disorders: past, present, and future. *Neurosurgery* 2009;64:1029–1038, discussion 38–42.
- 19 Gallay MN, Jeanmonod D, Liu J, Morel A: Human pallidothalamic and cerebellothalamic tracts: anatomical basis for functional stereotactic neurosurgery. *Brain Struct Funct* 2008;212:443–463.
- 20 Groppa S, Herzog J, Falk D, Riedel C, Deuschl G, Volkmann J: Physiological and anatomical decomposition of subthalamic neurostimulation effects in essential tremor. *Brain* 2014;137:109–121.
- 21 Schlaier J, Anthofer J, Steib K, Fellner C, Rothenfusser E, Brawanski A, Lange M: Deep brain stimulation for essential tremor: targeting the dentato-rubro-thalamic tract? *Neuro-modulation* 2015;18:105–112.
- 22 Carrillo-Ruiz JD, Velasco F, Jiménez F, Velasco AL, Castro G, Soto J, Salcido V: Prelemniscal radiations neuromodulation in Parkinson disease's treatment; in Carrillo-Ruiz (ed): *Topics in Neuromodulation Treatment*. Rijeka, InTech, 2012.
- 23 Plaha P, Patel NK, Gill SS: Stimulation of the subthalamic region for essential tremor. *J Neurosurg* 2004;101:48–54.
- 24 Plaha P, Ben-Shlomo Y, Patel NK, Gill SS: Stimulation of the caudal zona incerta is superior to stimulation of the subthalamic nucleus in improving contralateral parkinsonism. *Brain* 2006;129:1732–1747.
- 25 Carrillo-Ruiz JD, Velasco F, Jimenez F, Castro G, Velasco AL, Hernandez JA, Ceballos J, Velasco M: Bilateral electrical stimulation of prelemniscal radiations in the treatment of advanced Parkinson's disease. *Neurosurgery* 2008;62:347–359.
- 26 Kitagawa M, Murata J, Uesugi H, Kikuchi S, Saito H, Tashiro K, Sawamura Y: Two-year follow-up of chronic stimulation of the posterior subthalamic white matter for tremor-dominant Parkinson's disease. *Neurosurgery* 2005;56:281–289.
- 27 Keane M, Deyo S, Abosch A, Bajwa JA, Johnson MD: Improved spatial targeting with directionally segmented deep brain stimulation leads for treating essential tremor. *J Neural Eng* 2012;9:046005.
- 28 Zonenshayn M, Sterio D, Kelly PJ, Rezaei AR, Beric A: Location of the active contact within the subthalamic nucleus (STN) in the treatment of idiopathic Parkinson's disease. *Surg Neurol* 2004;62:216–226.
- 29 Weise LM, Seifried C, Eibach S, Gasser T, Roper J, Seifert V, Hilker R: Correlation of active contact positions with the electrophysiological and anatomical subdivisions of the subthalamic nucleus in deep brain stimulation. *Stereotact Funct Neurosurg* 2013;91:298–305.
- 30 Pollo C, Vingerhoets F, Pralong E, Ghika J, Maeder P, Meuli R, Thiran JP, Villemure JG: Localization of electrodes in the subthalamic nucleus on magnetic resonance imaging. *J Neurosurg* 2007;106:36–44.
- 31 Bejjani B, Damier P, Arnulf I, Bonnet AM, Vidailhet M, Dormont D, Pidoux B, Cornu P, Marsault C, Agid Y: Pallidal stimulation for Parkinson's disease. Two targets? *Neurology* 1997;49:1564–1569.
- 32 Tommasi G, Lopiano L, Zibetti M, Cinquapalmi A, Fronda C, Bergamasco B, Ducati A, Lanotte M: Freezing and hypokinesia of gait induced by stimulation of the subthalamic region. *J Neurol Sci* 2007;258:99–103.
- 33 Fleury V, Pollak P, Gere J, Tommasi G, Romito L, Combesure C, Bardinet E, Chabardes S, Momjian S, Krainik A, Burkhard P, Yelnik J, Krack P: Subthalamic stimulation may inhibit the beneficial effects of levodopa on akinesia and gait. *Mov Disord* 2016;31:1389–1397.
- 34 Fytagoridis A, Astrom M, Wardell K, Blomstedt P: Stimulation-induced side effects in the posterior subthalamic area: distribution, characteristics and visualization. *Clin Neurol Neurosurg* 2013;115:65–71.
- 35 Karlsson F, Unger E, Wahlgren S, Blomstedt P, Linder J, Nordh E, Zafar H, van Doorn J: Deep brain stimulation of caudal zona incerta and subthalamic nucleus in patients with Parkinson's disease: effects on diadochokinetic rate. *Parkinsons Dis* 2011;2011:605607.
- 36 Karlsson F, Blomstedt P, Olofsson K, Linder J, Nordh E, van Doorn J: Control of phonatory onset and offset in Parkinson patients following deep brain stimulation of the subthalamic nucleus and caudal zona incerta. *Parkinsonism Relat Disord* 2012;18:824–827.
- 37 Klein JC, Barbe MT, Seifried C, Baudrexel S, Runge M, Maarouf M, Gasser T, Hattingen E, Liebig T, Deichmann R, Timmermann L, Weise L, Hilker R: The tremor network targeted by successful VIM deep brain stimulation in humans. *Neurology* 2012;78:787–795.
- 38 Calabrese E, Hickey P, Hulette C, Zhang J, Parente B, Lad SP, Johnson GA: Postmortem diffusion MRI of the human brainstem and thalamus for deep brain stimulator electrode localization. *Hum Brain Mapp* 2015;36:3167–3178.
- 39 Herzog J, Hamel W, Wenzelburger R, Potter M, Pinsker MO, Bartussek J, Morsnowski A, Steigerwald F, Deuschl G, Volkmann J: Kinematic analysis of thalamic versus subthalamic neurostimulation in postural and intention tremor. *Brain* 2007;130:1608–1625.
- 40 Coenen VA, Allert N, Madler B: A role of diffusion tensor imaging fiber tracking in deep brain stimulation surgery: DBS of the dentato-rubro-thalamic tract (drt) for the treatment of therapy-refractory tremor. *Acta Neurochir* 2011;153:1579–1585.
- 41 Coenen VA, Allert N, Paus S, Kronenburger M, Urbach H, Madler B: Modulation of the cerebello-thalamo-cortical network in thalamic deep brain stimulation for tremor: a diffusion tensor imaging study. *Neurosurgery* 2014;75:657–669.
- 42 Coenen VA, Madler B, Schiffbauer H, Urbach H, Allert N: Individual fiber anatomy of the subthalamic region revealed with diffusion tensor imaging: a concept to identify the deep brain stimulation target for tremor suppression. *Neurosurgery* 2011;68:1069–1076.
- 43 Hanson TL, Fuller AM, Lebedev MA, Turner DA, Nicoletis MA: Subcortical neuronal ensembles: an analysis of motor task association, tremor, oscillations, and synchrony in human patients. *J Neurosci* 2012;32:8620–8632.
- 44 Lim SY, Hodaie M, Fallis M, Poon YY, Mazzella F, Moro E: Gamma knife thalamotomy for disabling tremor: a blinded evaluation. *Arch Neurol* 2010;67:584–588.
- 45 Pollo C, Kaelin-Lang A, Oertel MF, Stieglitz L, Taub E, Fuhr P, Lozano AM, Raabe A, Schupbach M: Directional deep brain stimulation: an intraoperative double-blind pilot study. *Brain* 2014;137:2015–2026.